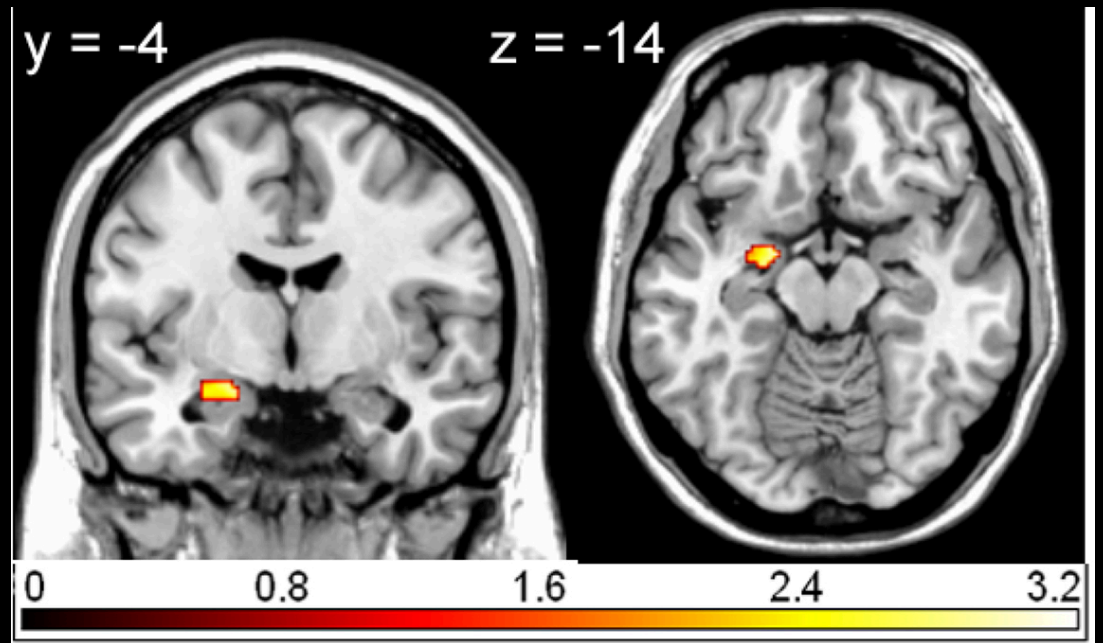


An Introduction to Neuroscience

Dr. Olav E Krigolson
krigolson@gmail.com



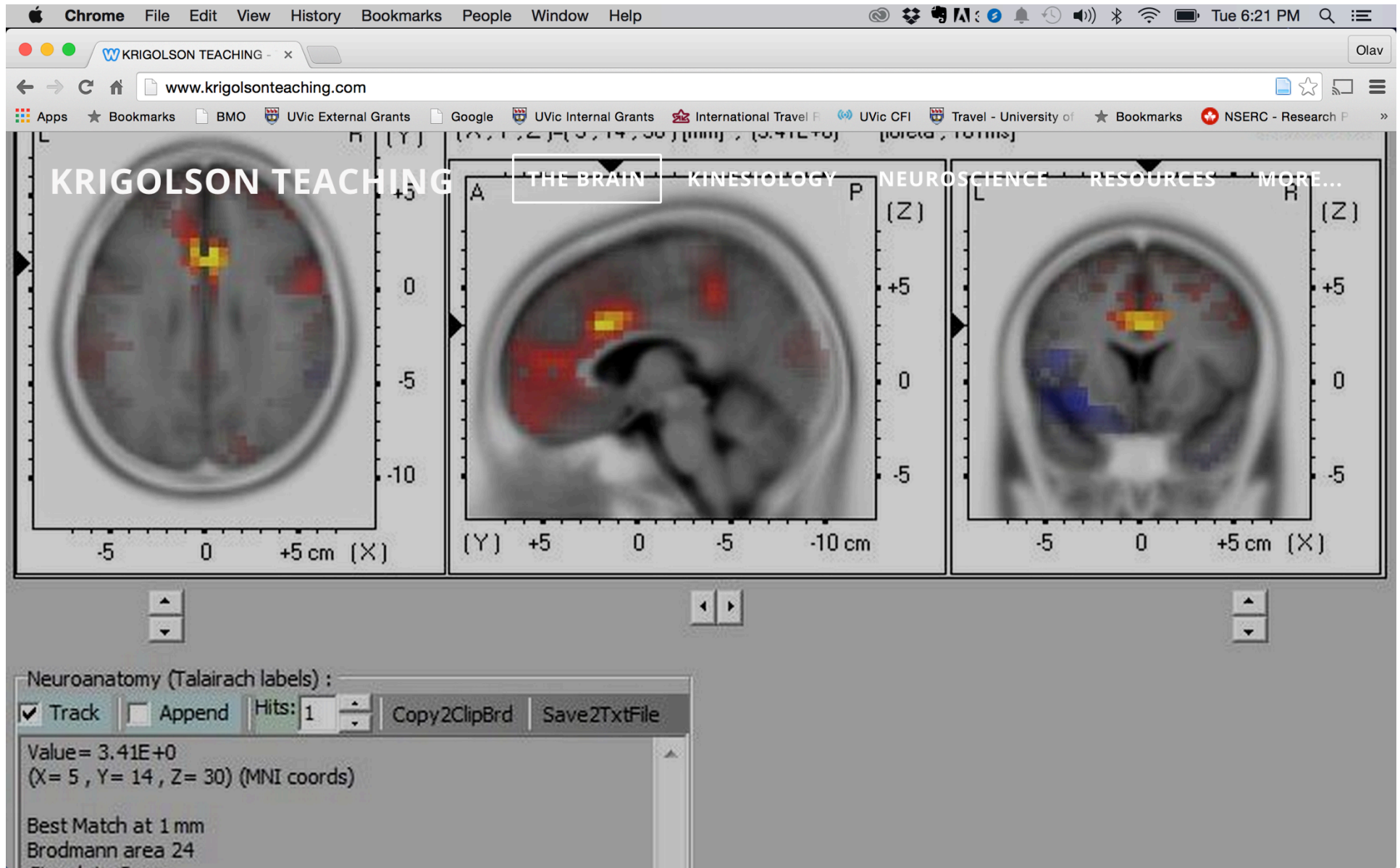
Tonight

Phantom Limbs

Sensation and Audition

MRI and fMRI

www.krigolsonteaching.com



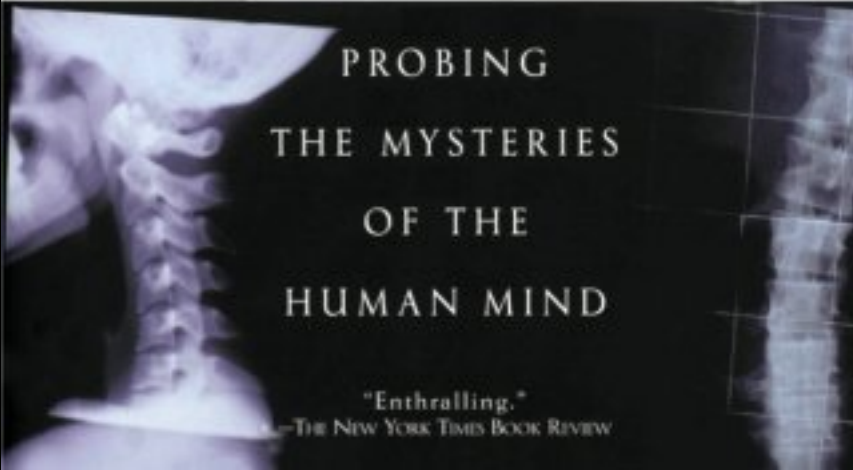
Phantom Limbs



PHANTOMS IN THE BRAIN

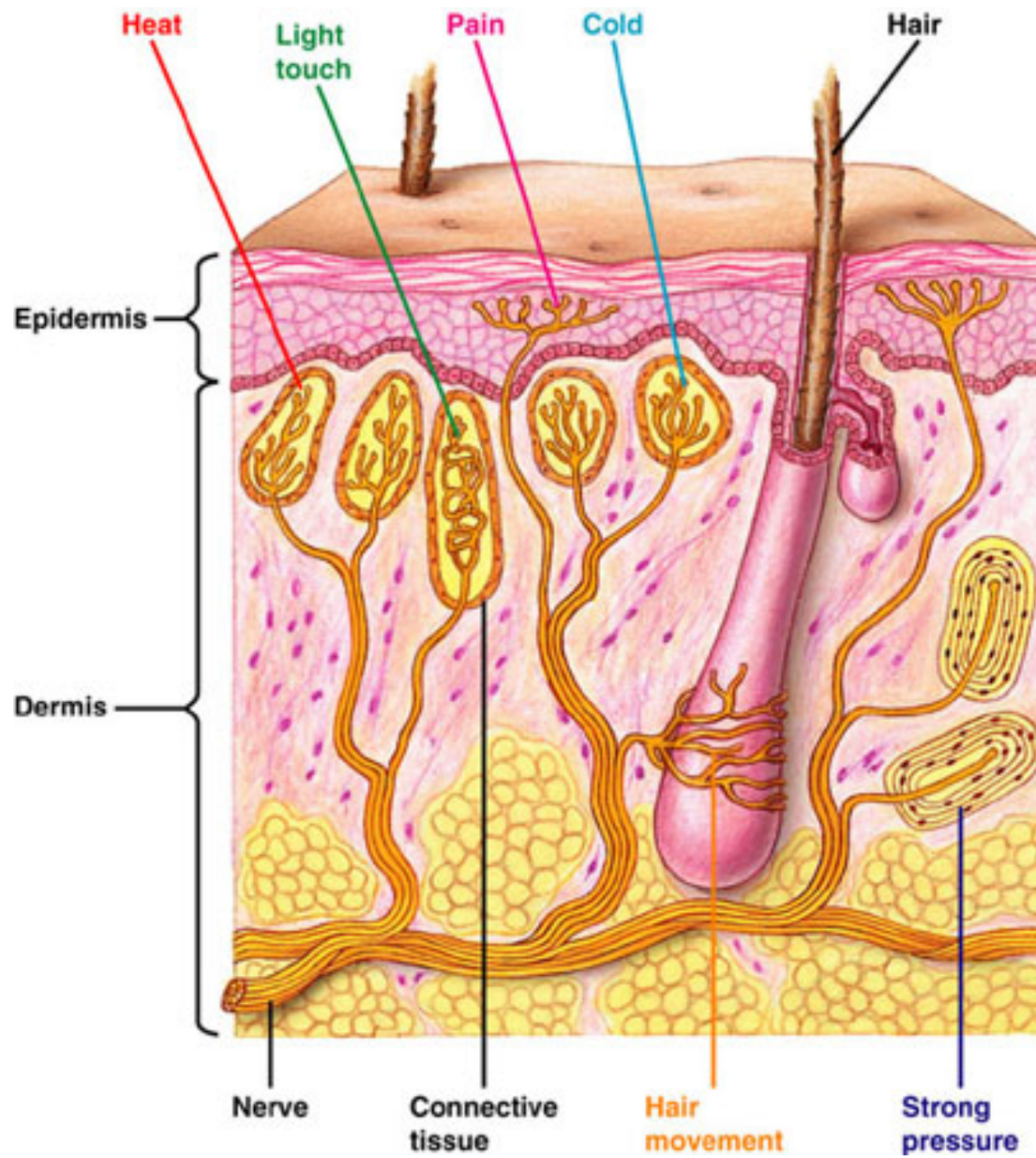
V.S. RAMACHANDRAN, M.D., PH.D.,
AND SANDRA BLAKESLEE

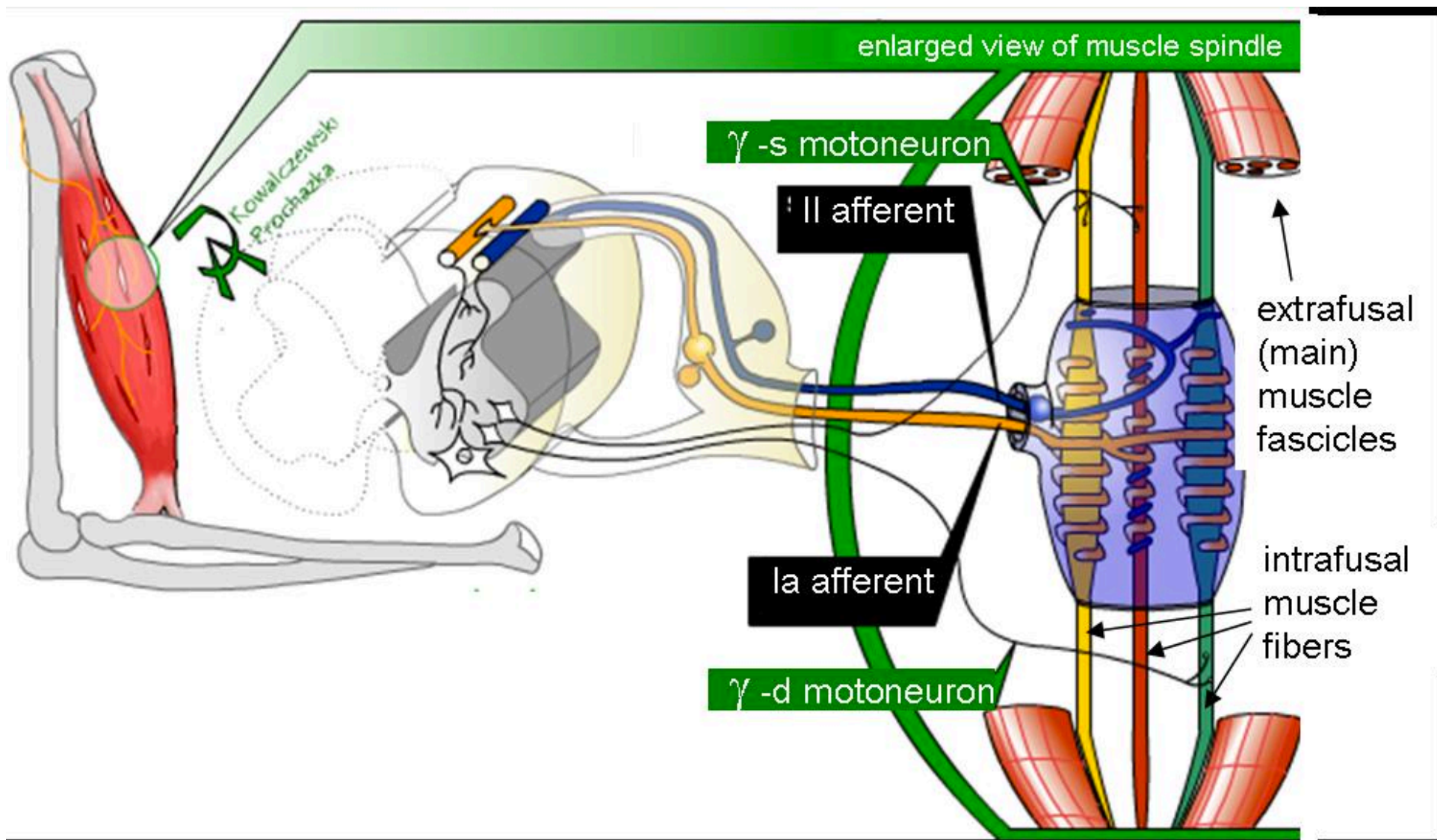
FOREWORD BY OLIVER SACKS, M.D.

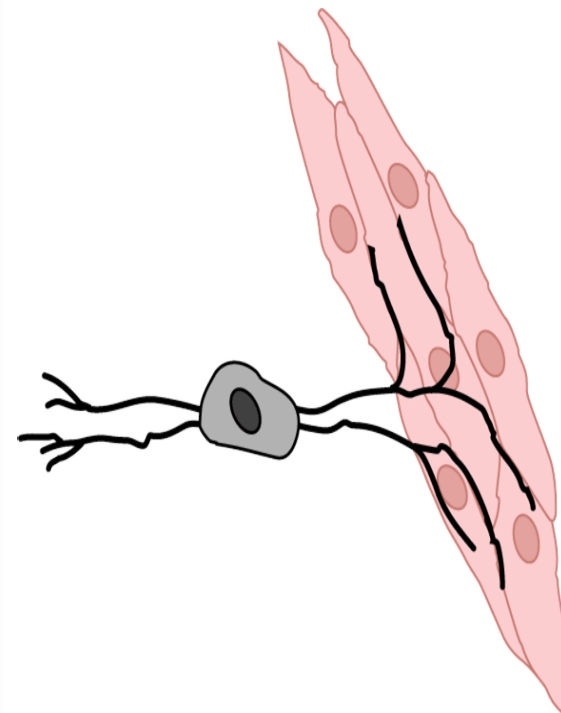
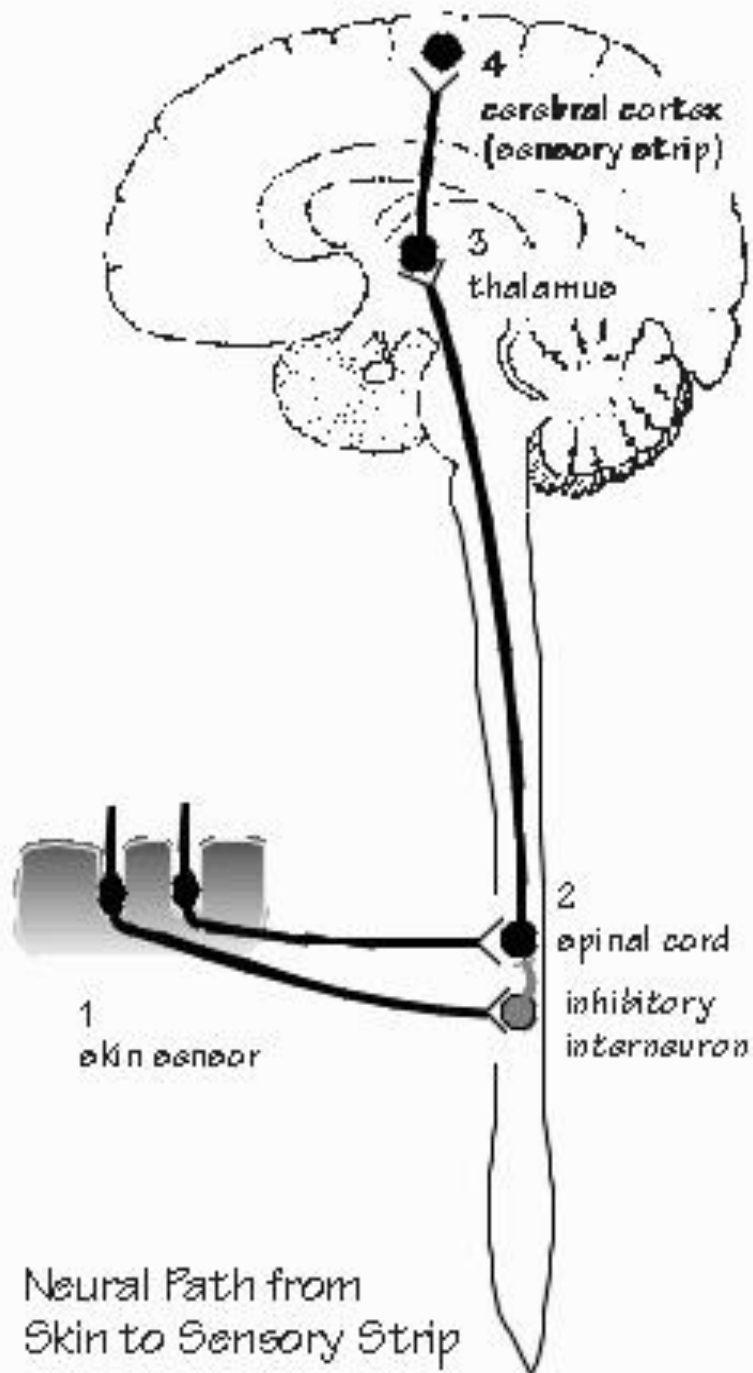


PROBING
THE MYSTERIES
OF THE
HUMAN MIND

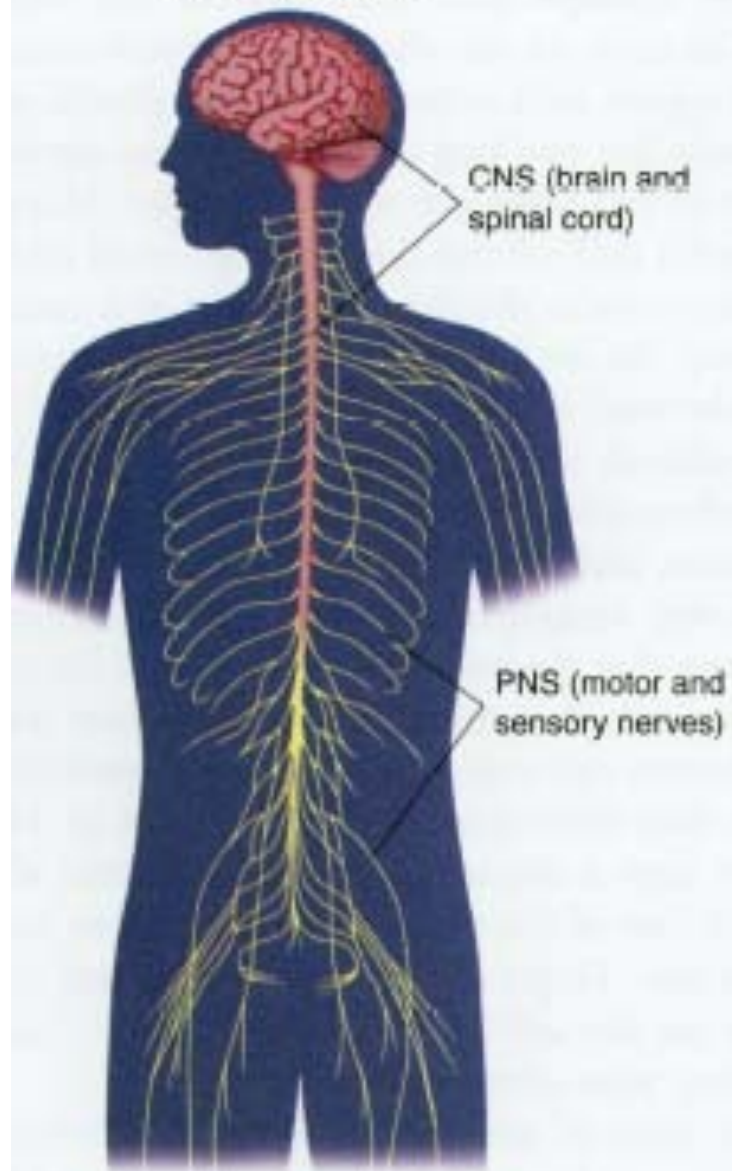
"Enthralling."
—THE NEW YORK TIMES BOOK REVIEW



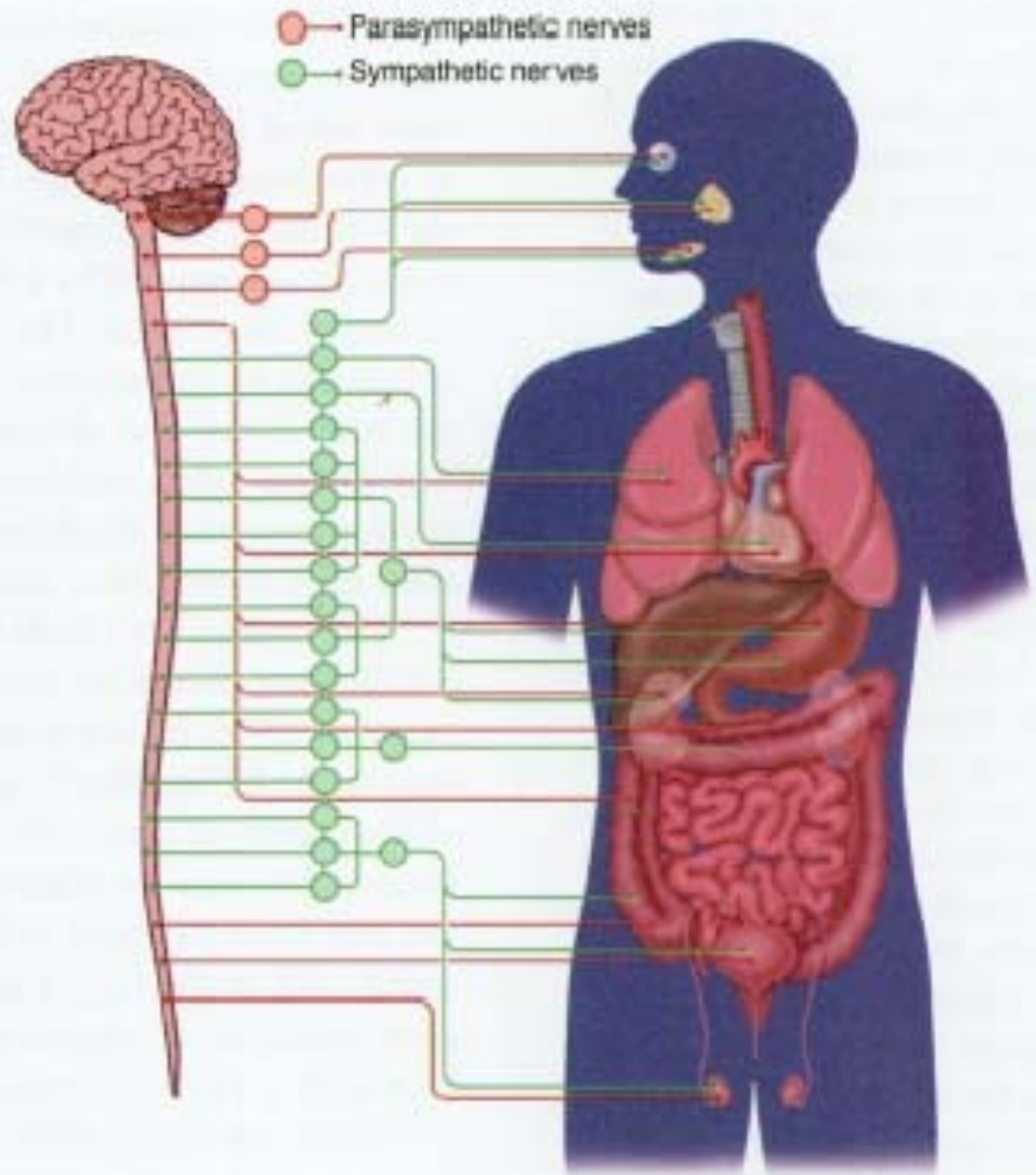


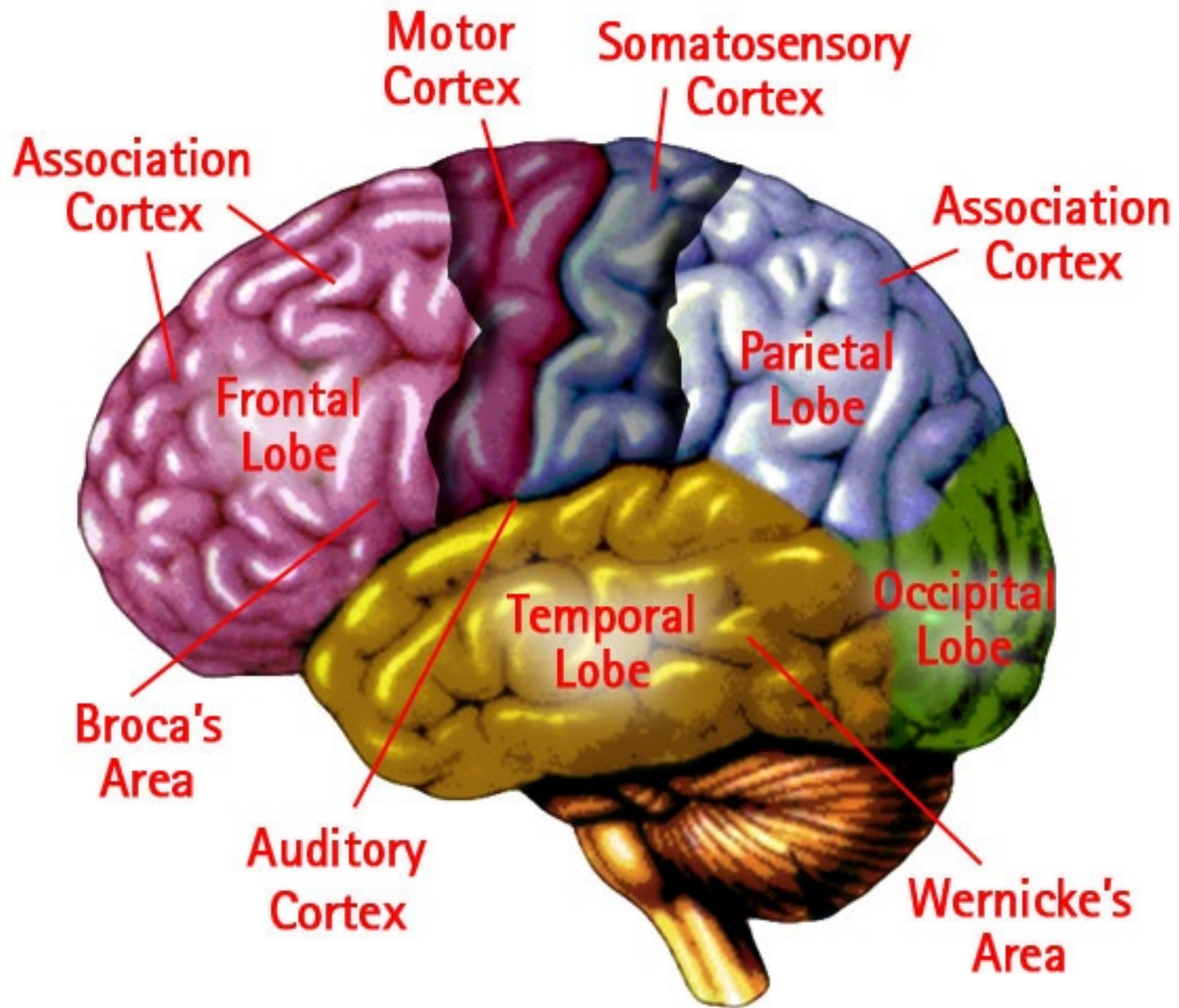


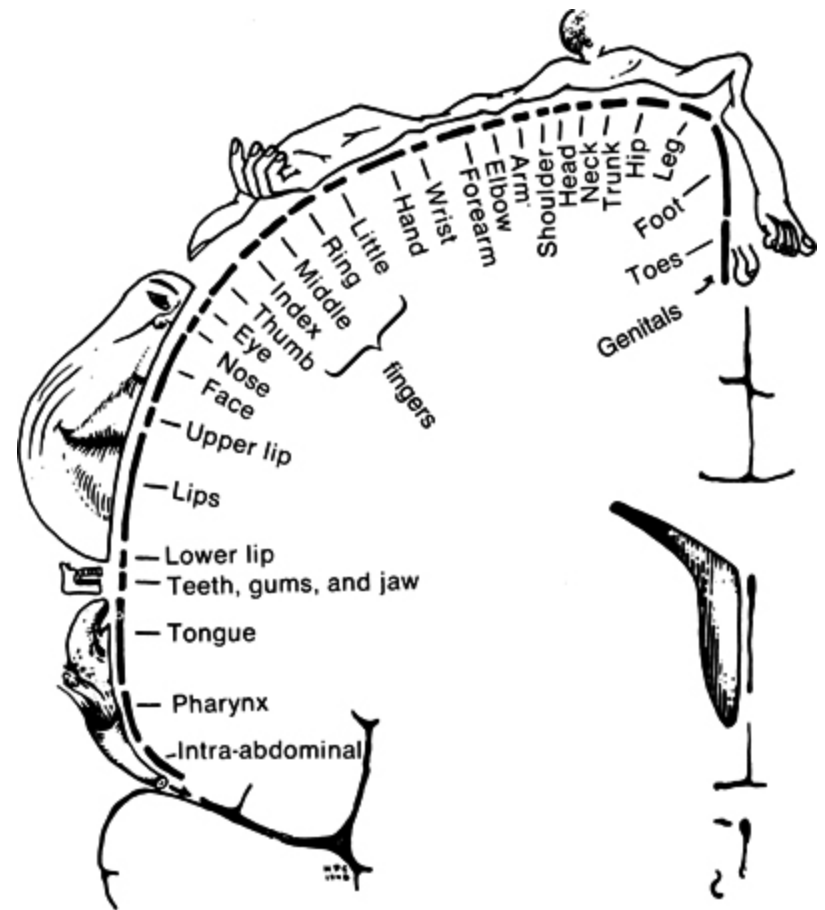
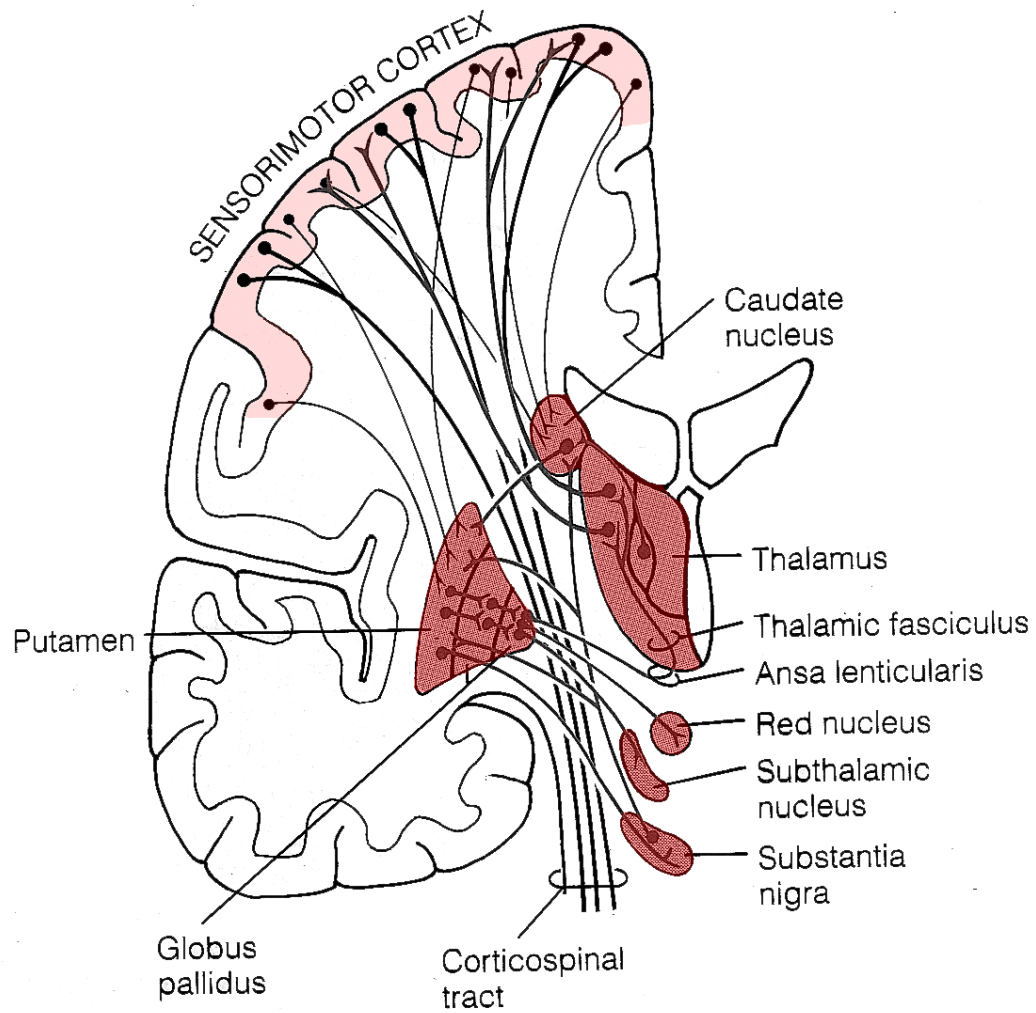
Central and peripheral nervous systems

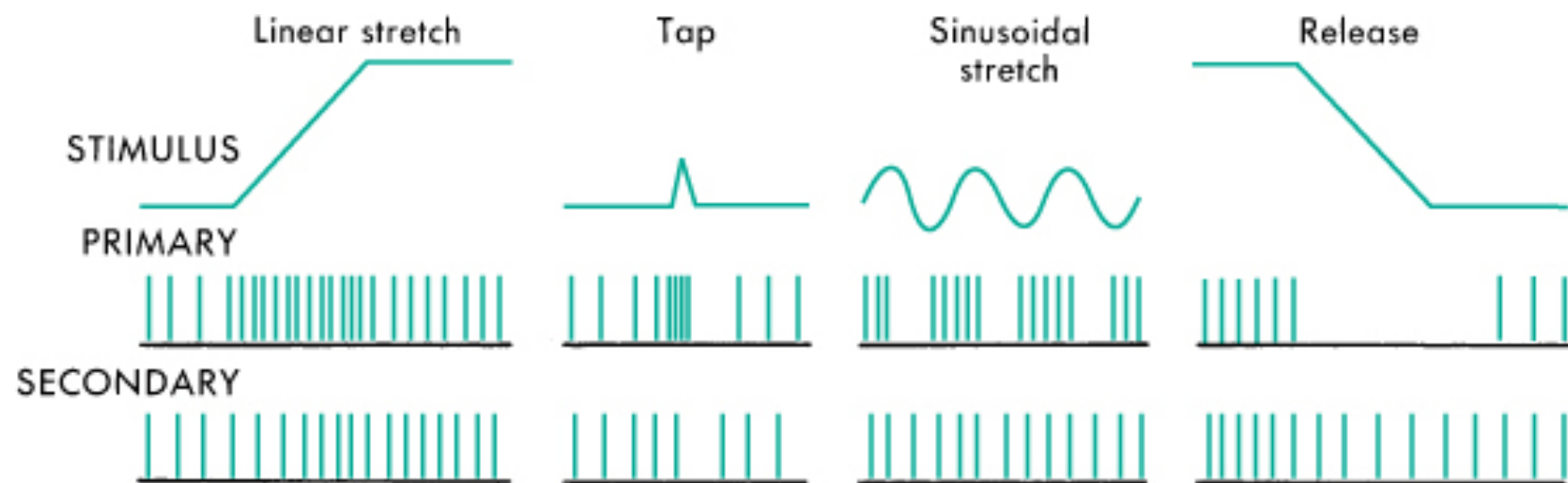


Autonomic nervous system



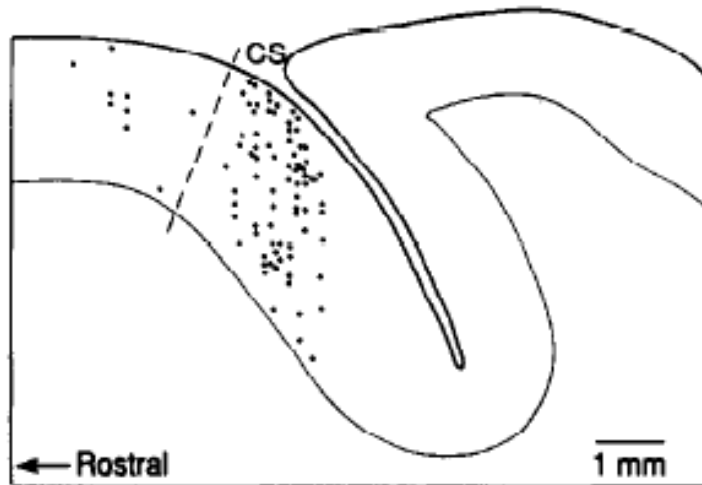







Picard, 1992


A CUTANEOUS RFs




B PROPRIOCEPTIVE RFs



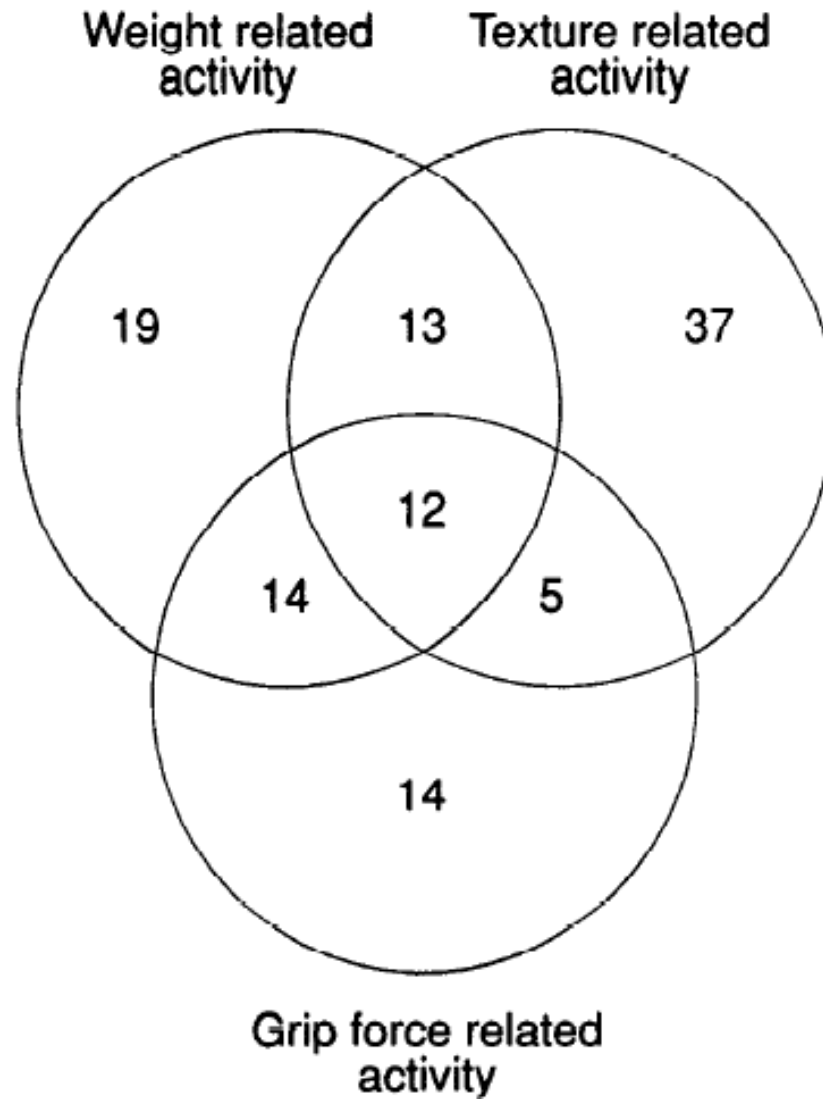
C TEXTURE-RELATED NEURONS



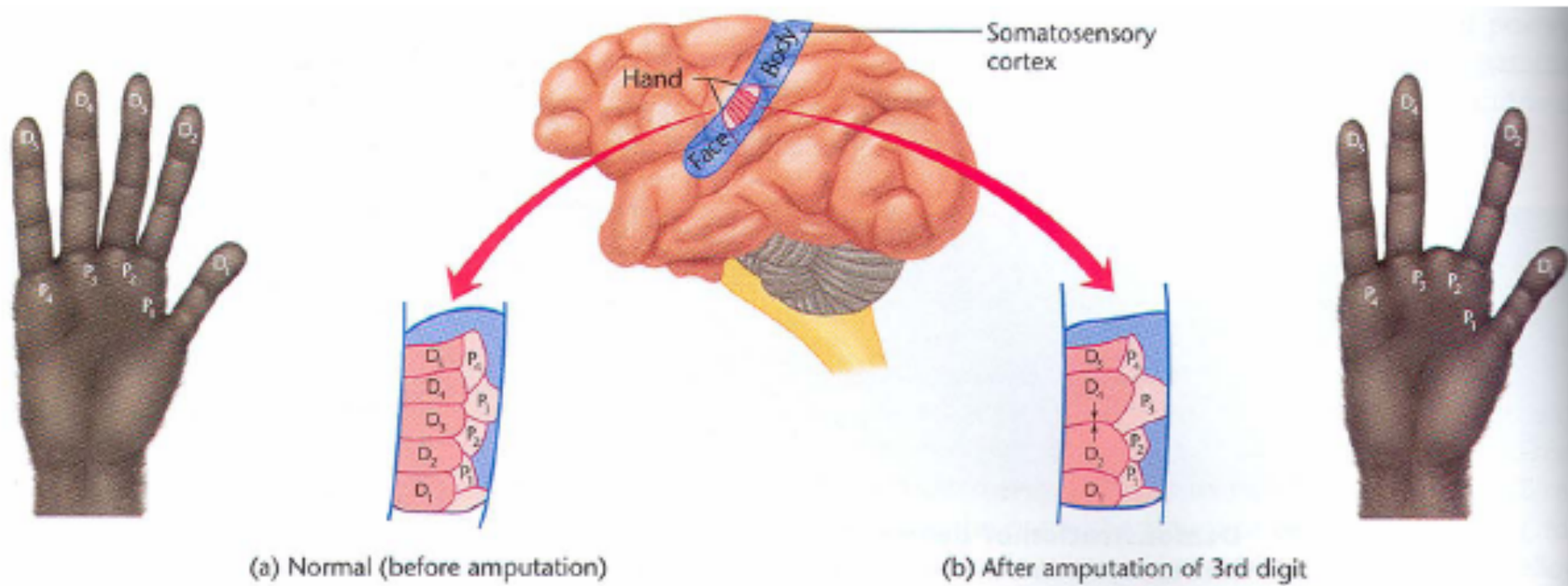
D WEIGHT-RELATED NEURONS



Picard, 1992



Phantom Limbs



Neural Plasticity

Face

Arm

Shoulder

Primary Sensory Layer

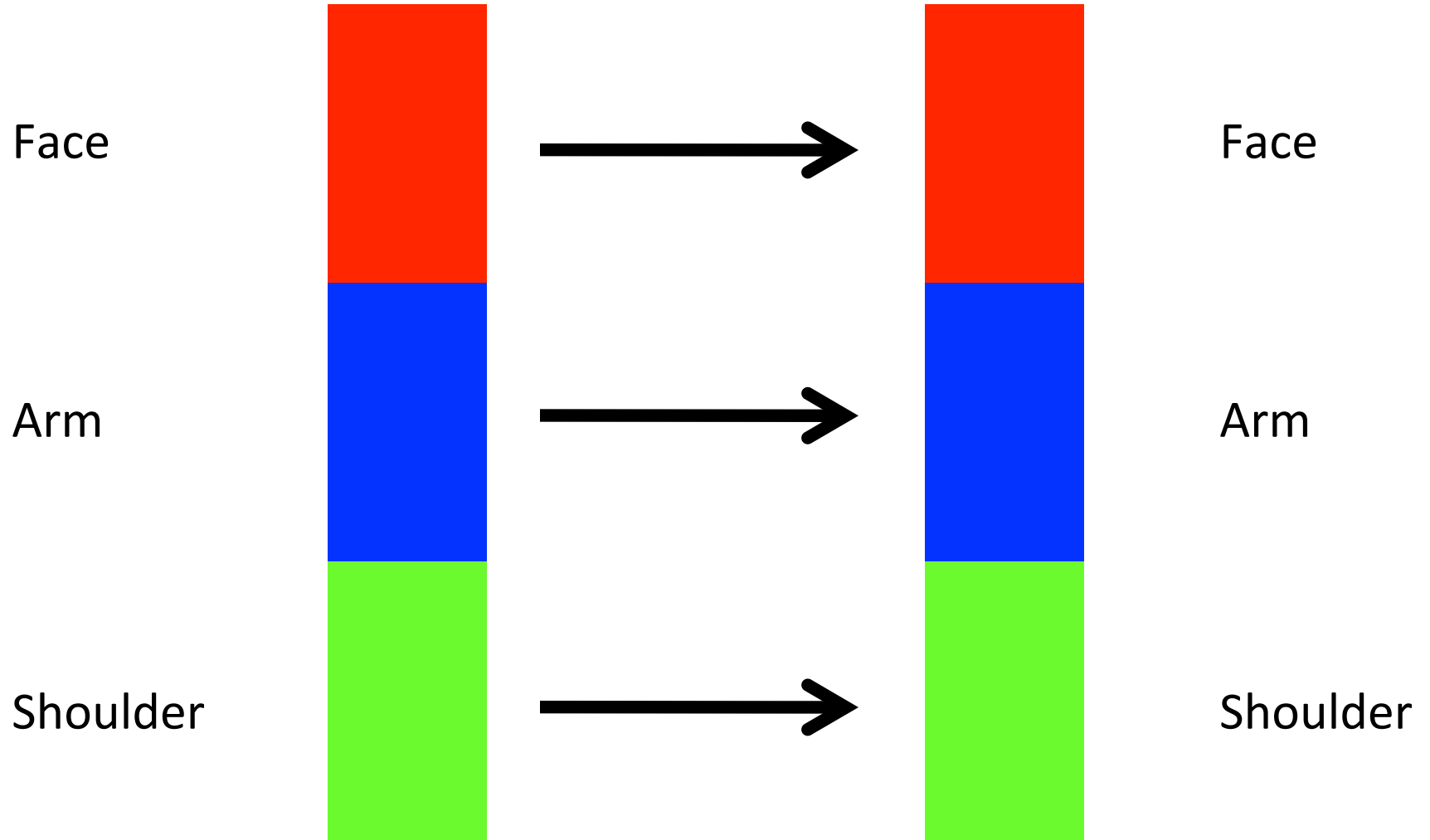


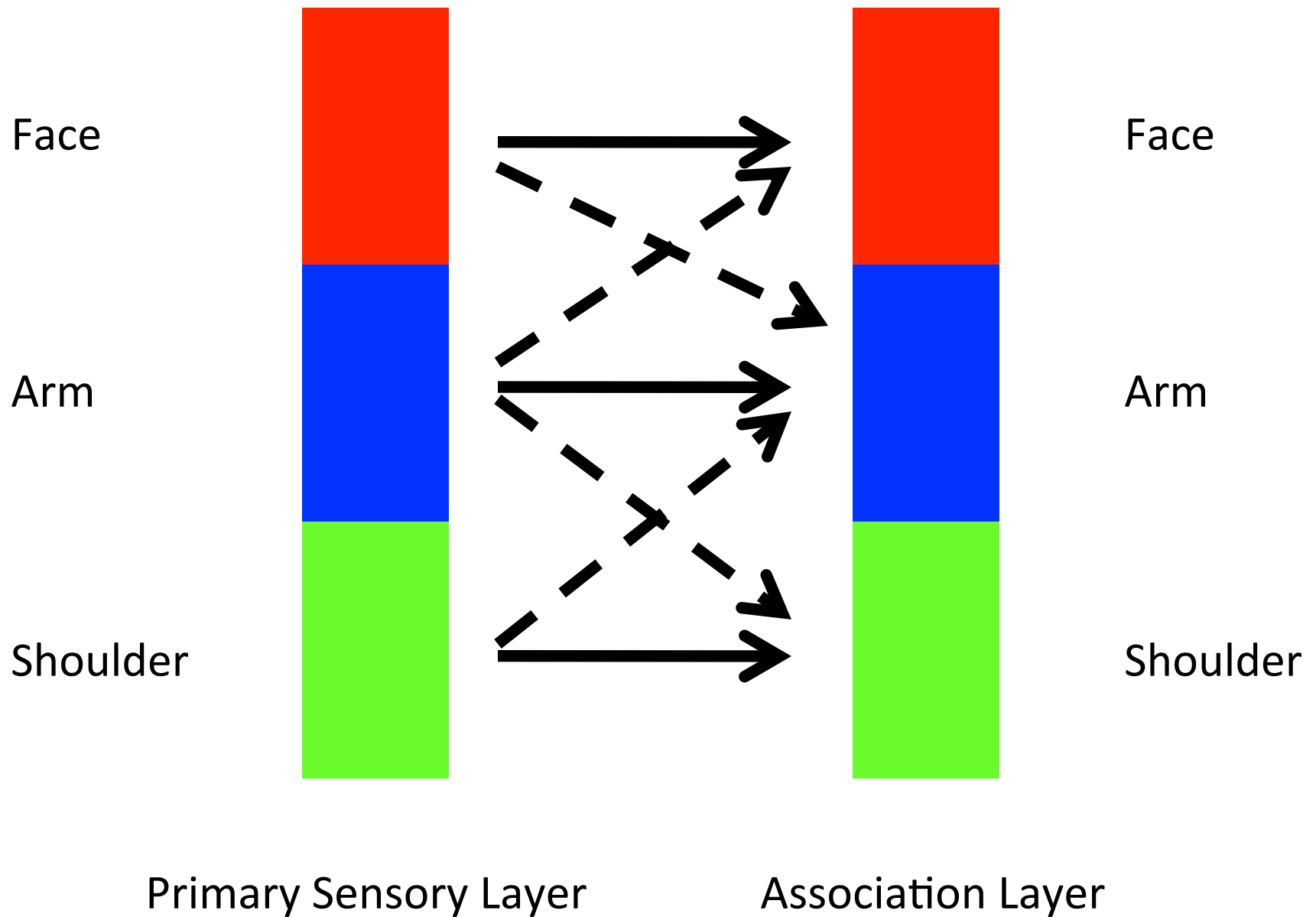
Association Layer

Face

Arm

Shoulder

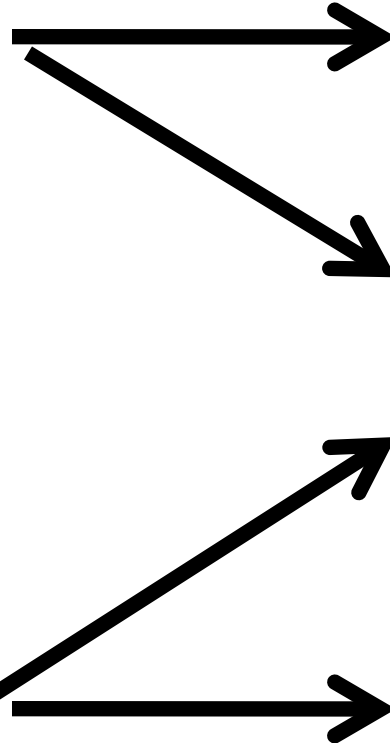





Face

Shoulder

Primary Sensory Layer



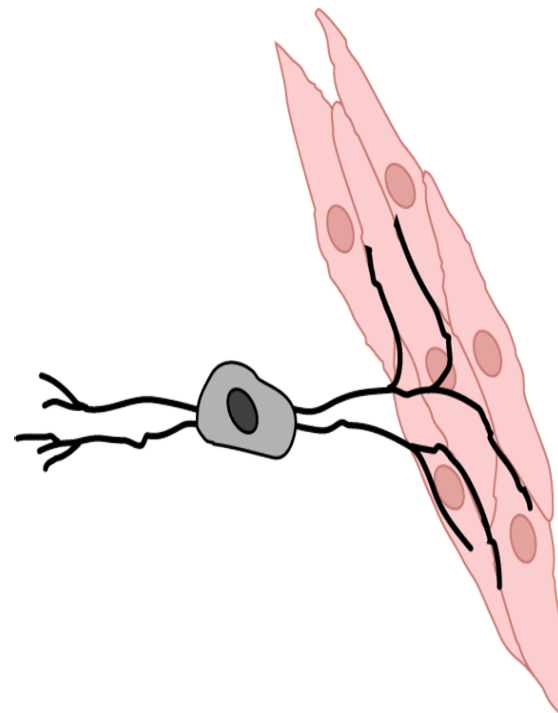
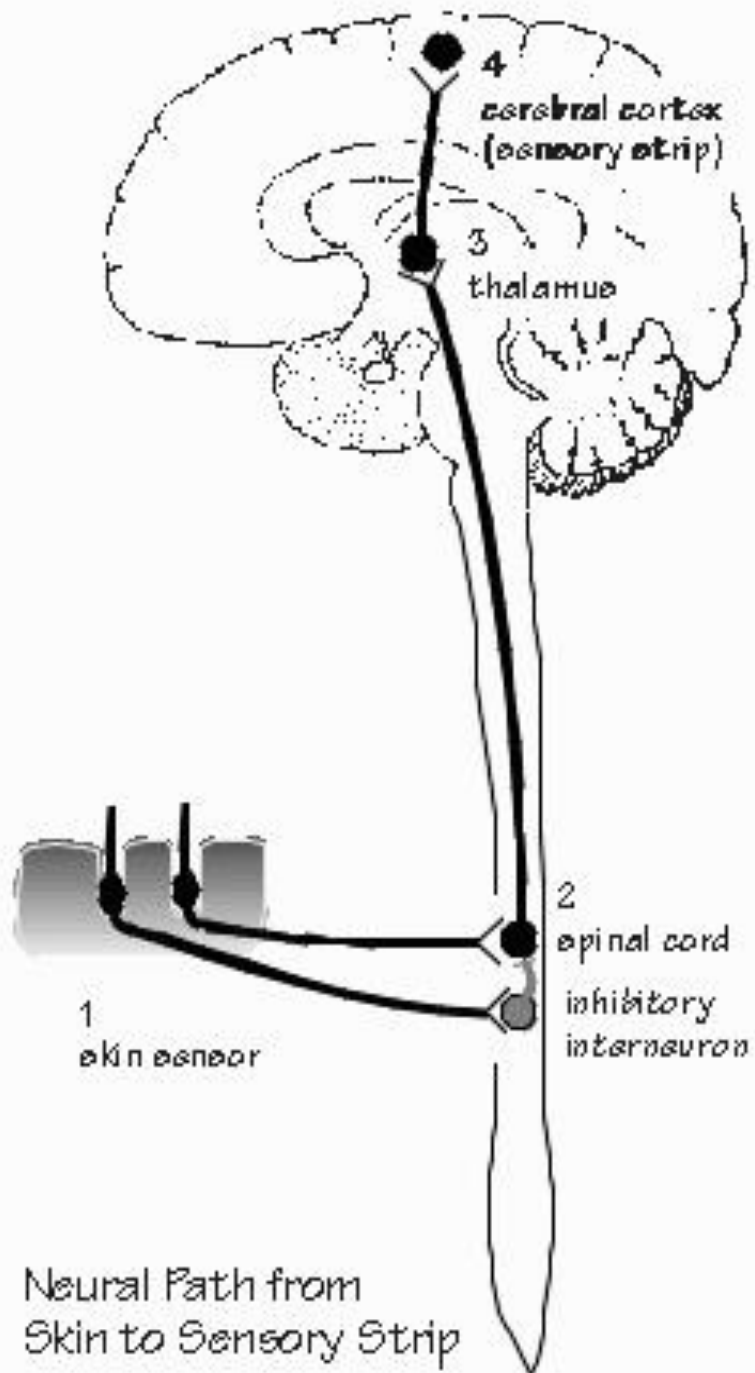
Face

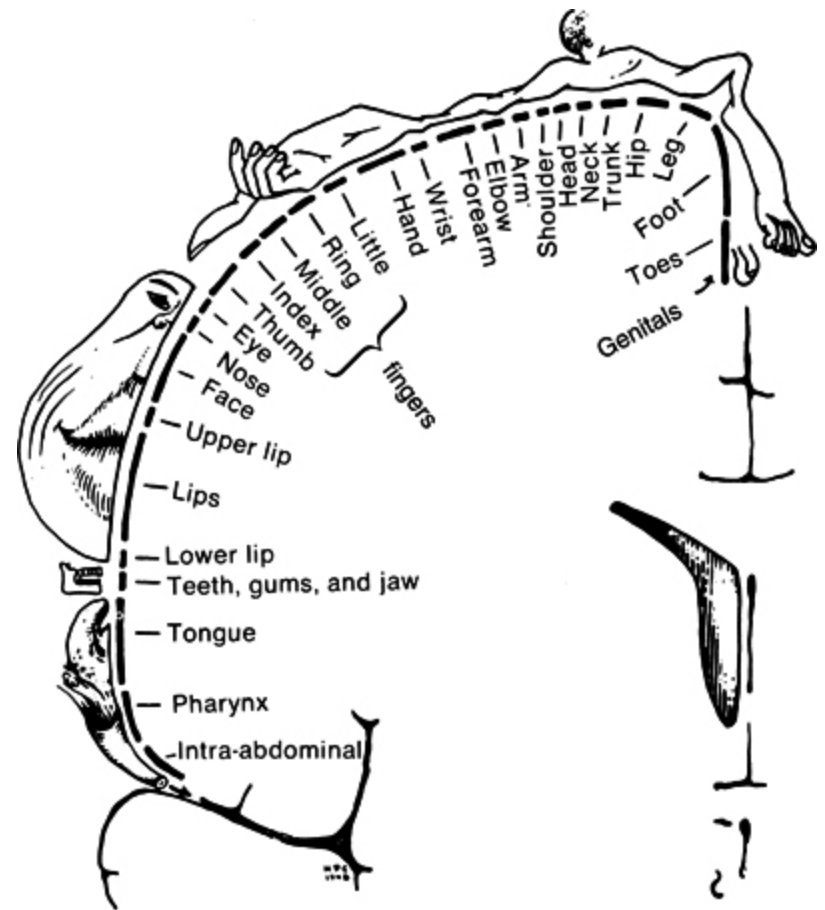
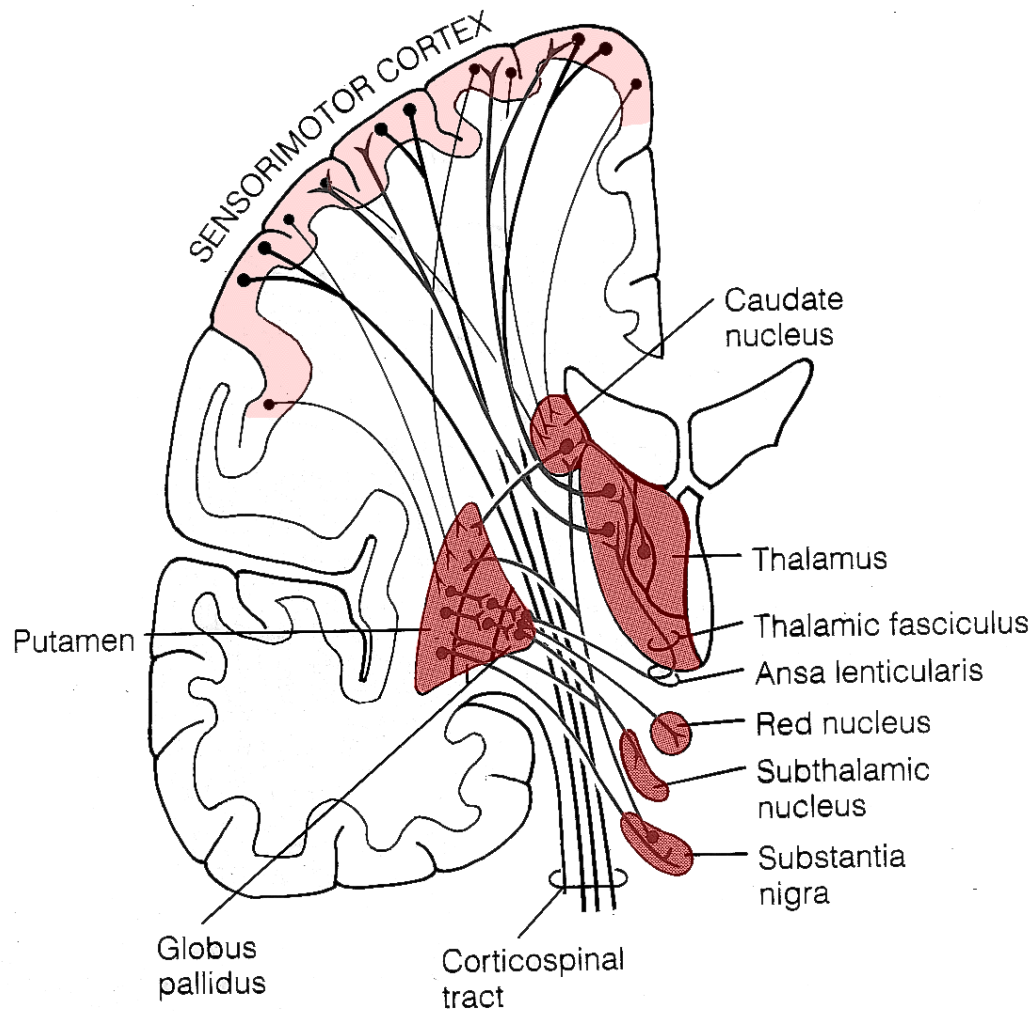
Arm

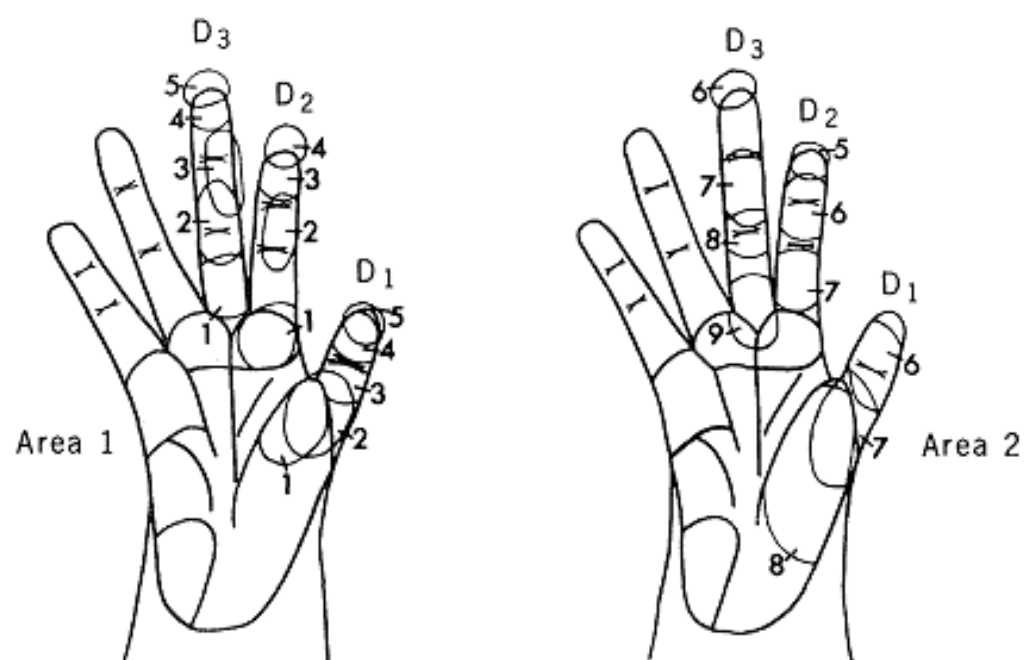
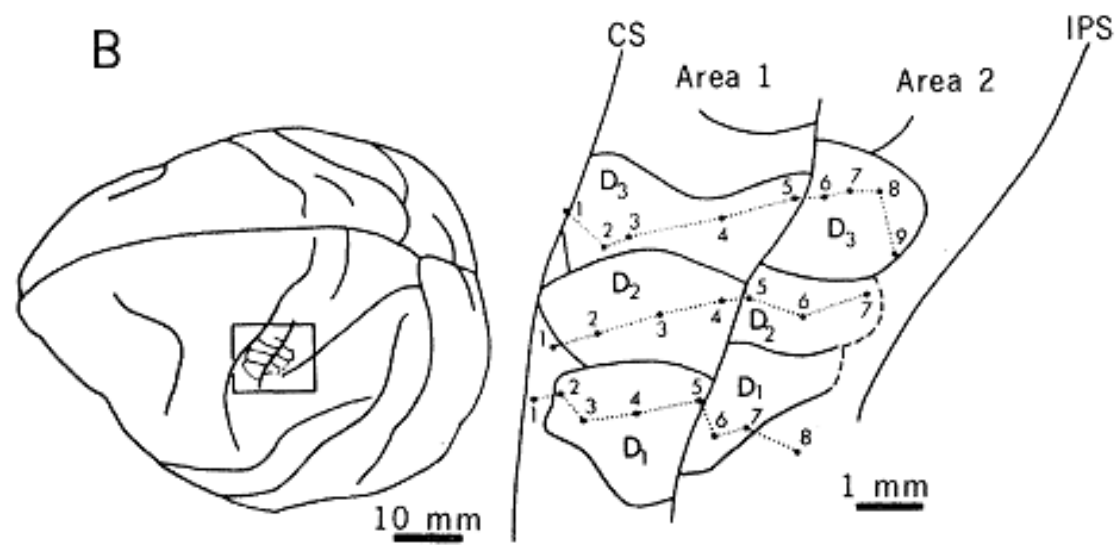
Shoulder

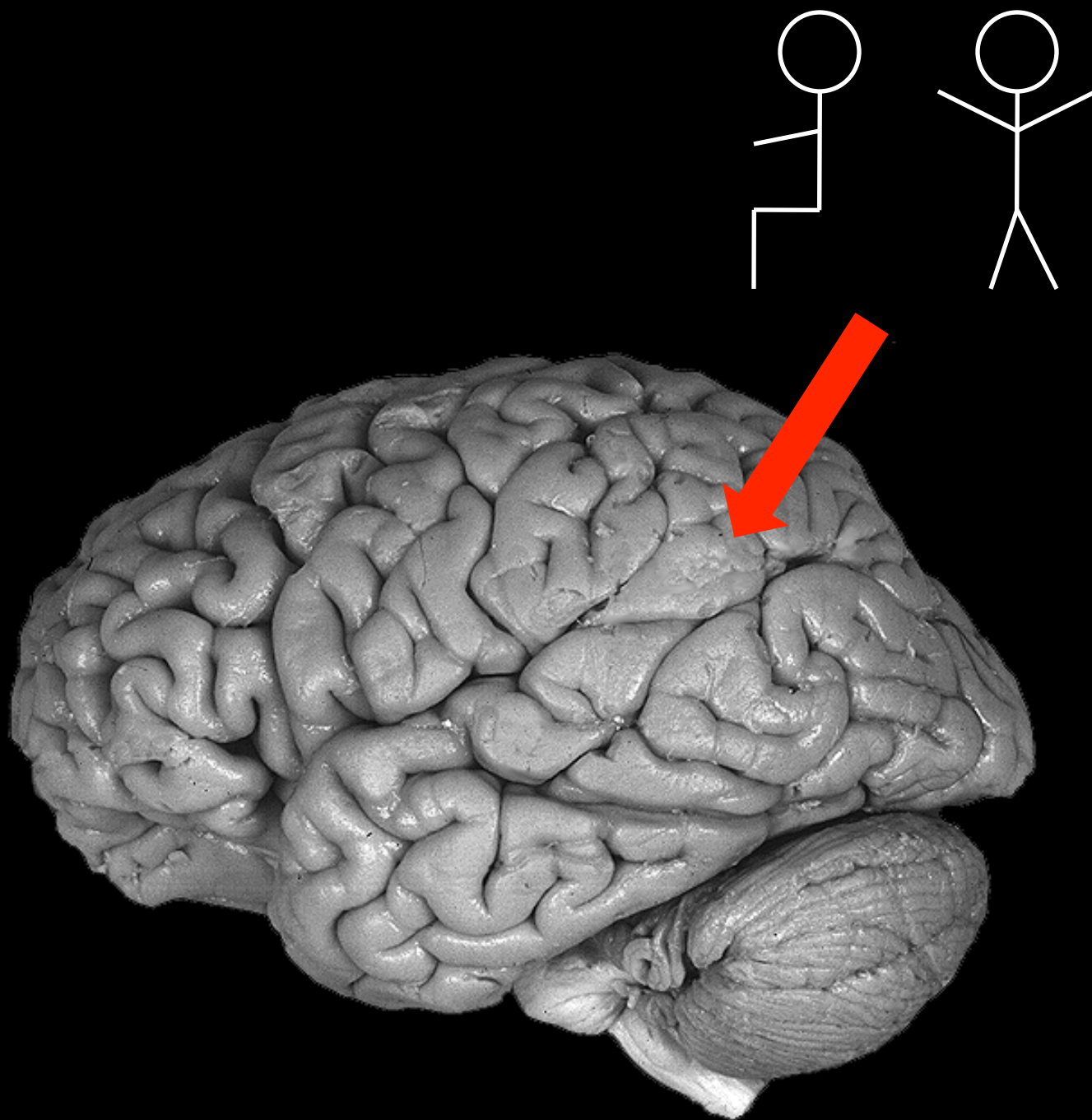
Association Layer

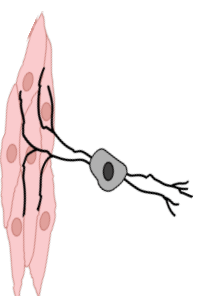
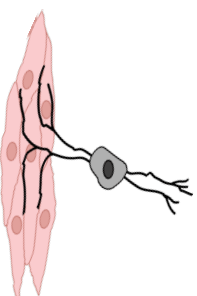
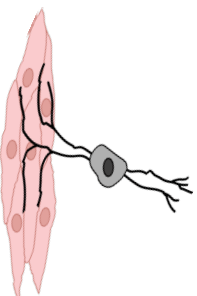
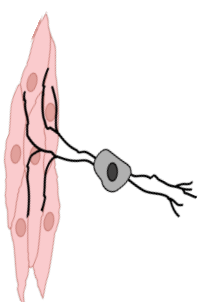
Body Image

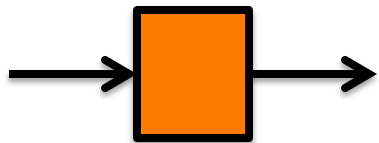
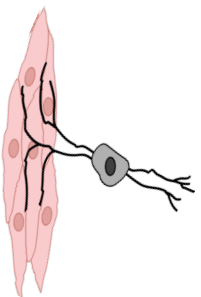

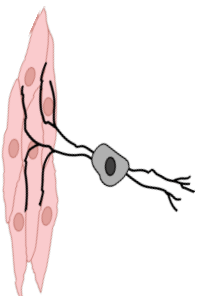

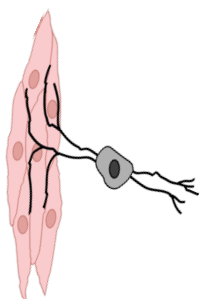


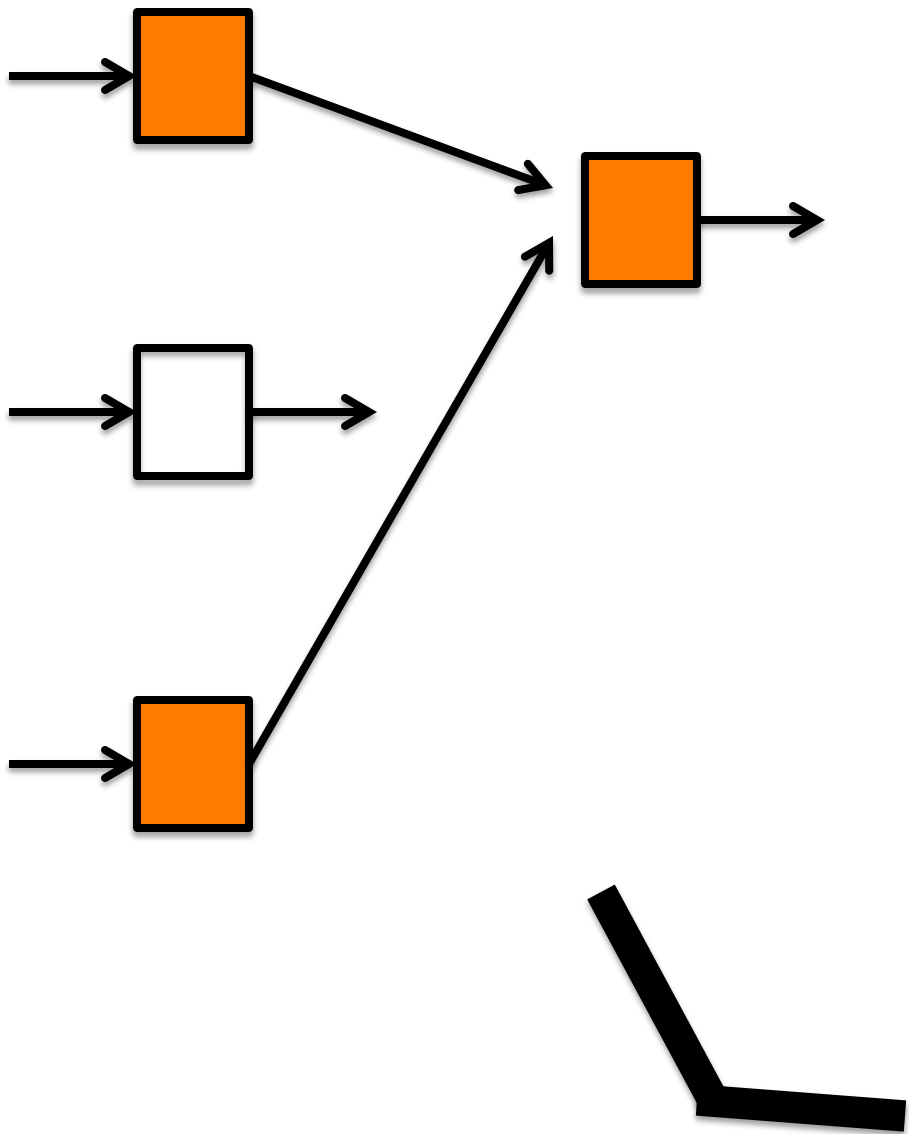
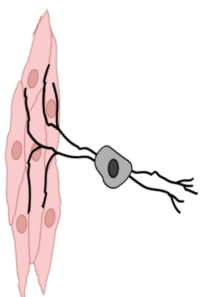
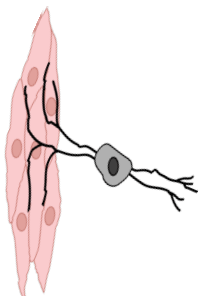
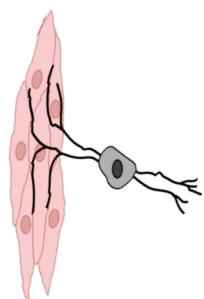


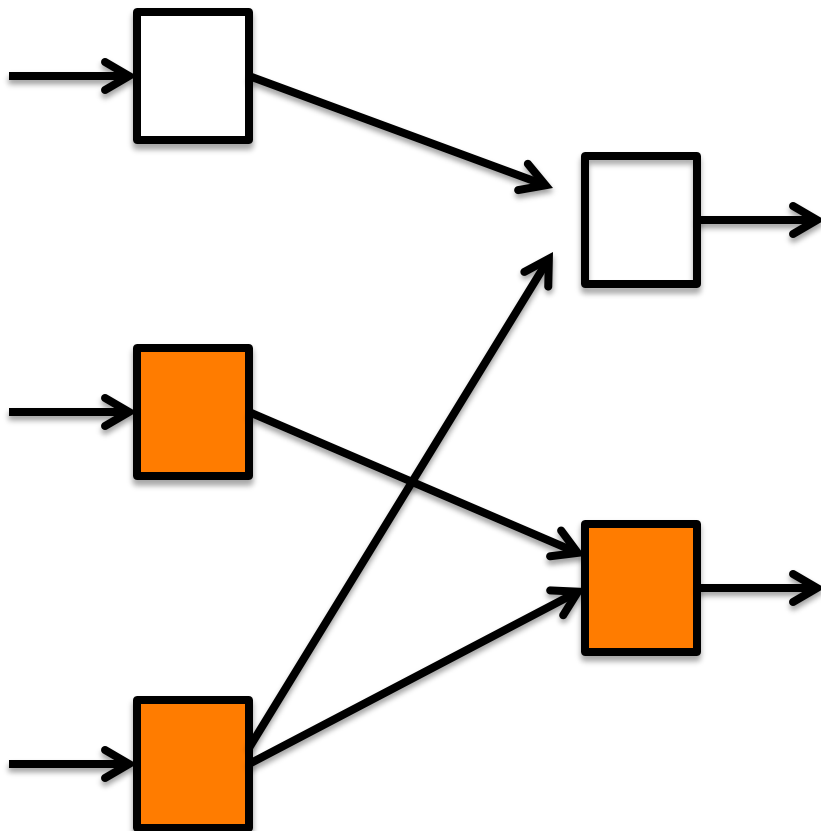
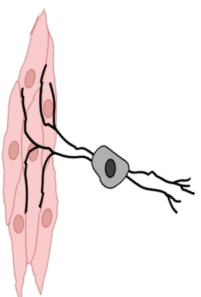
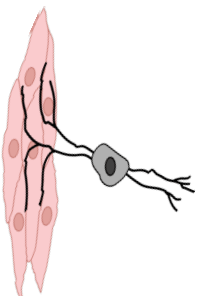
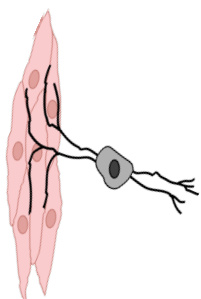


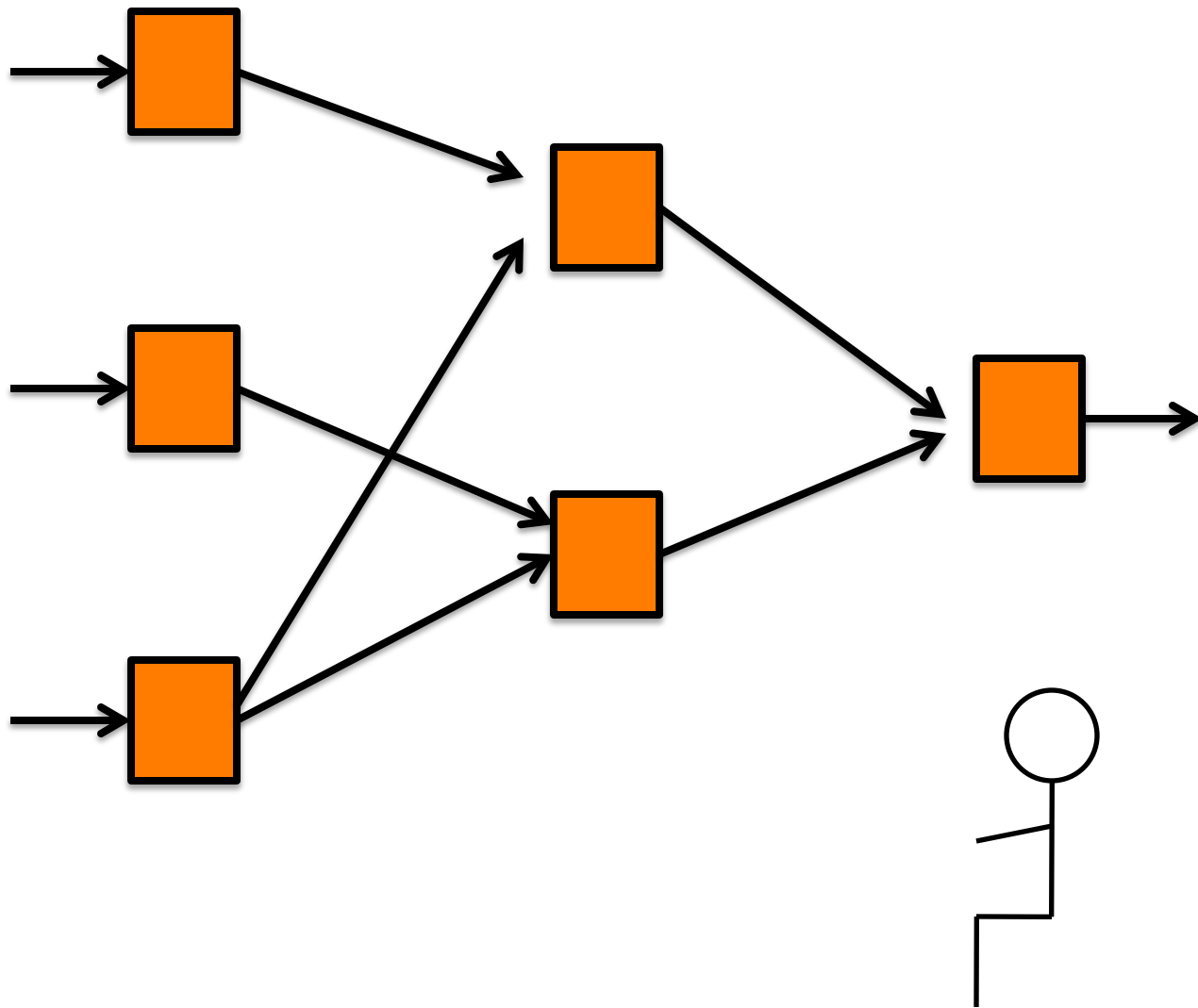
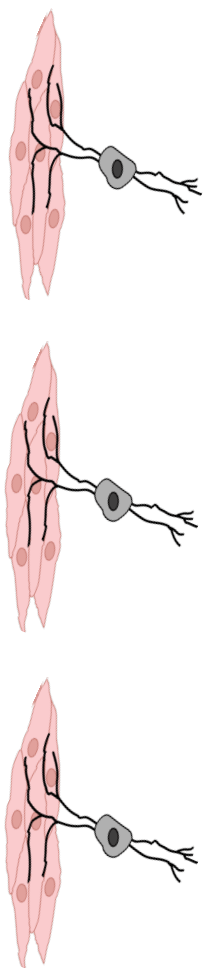












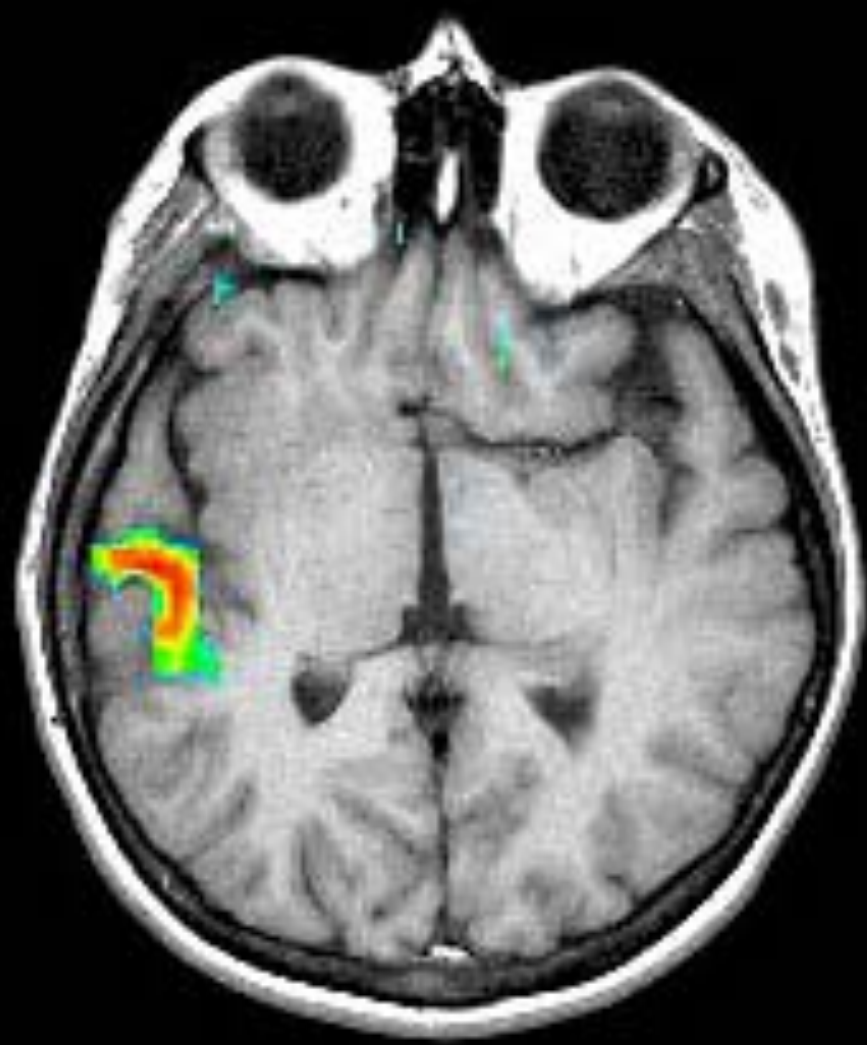
“BODY IMAGE” – the internal image and memory of one’s body in space and time

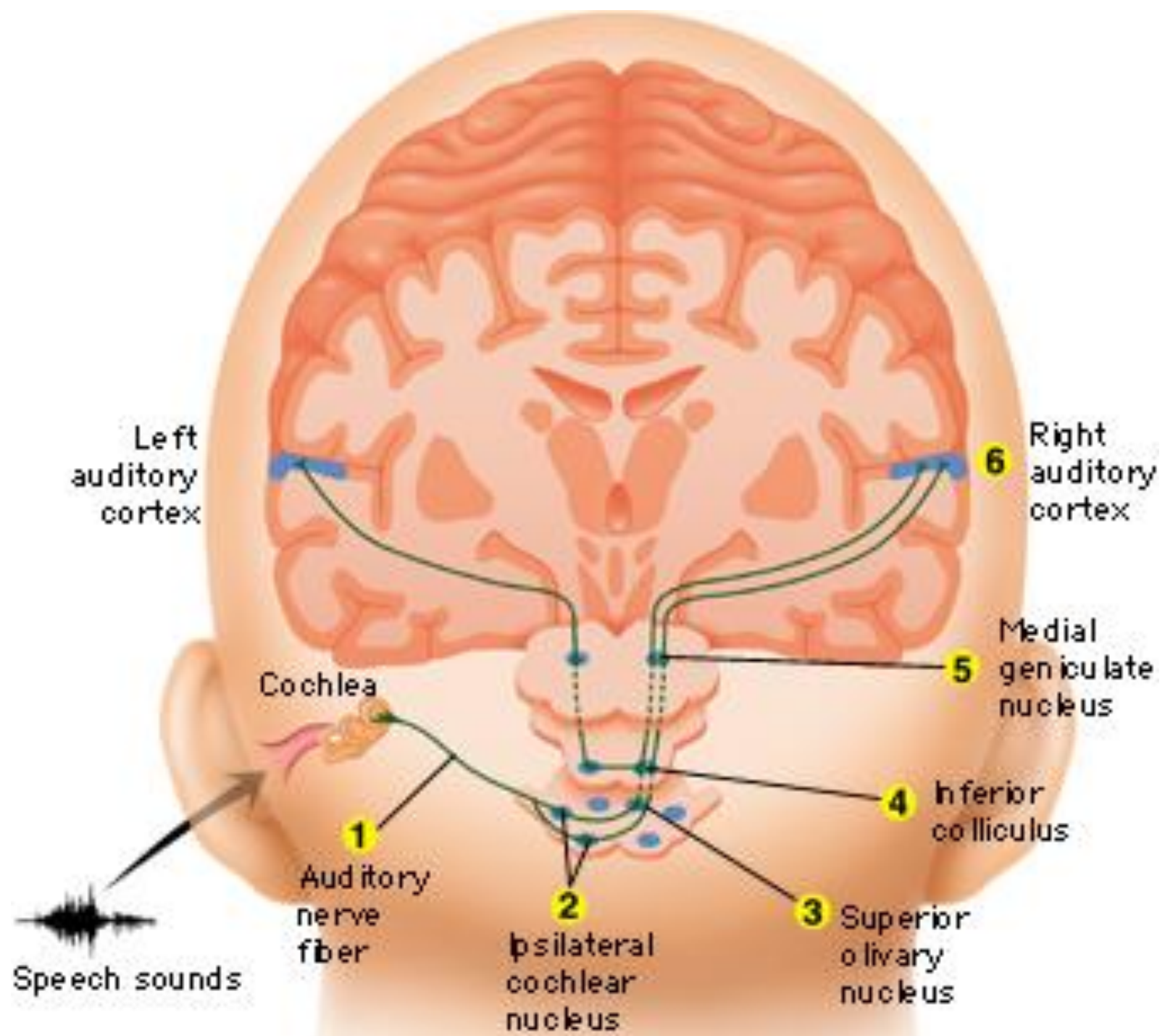
Generated in the parietal association area – sensory fb, visual fb, etc

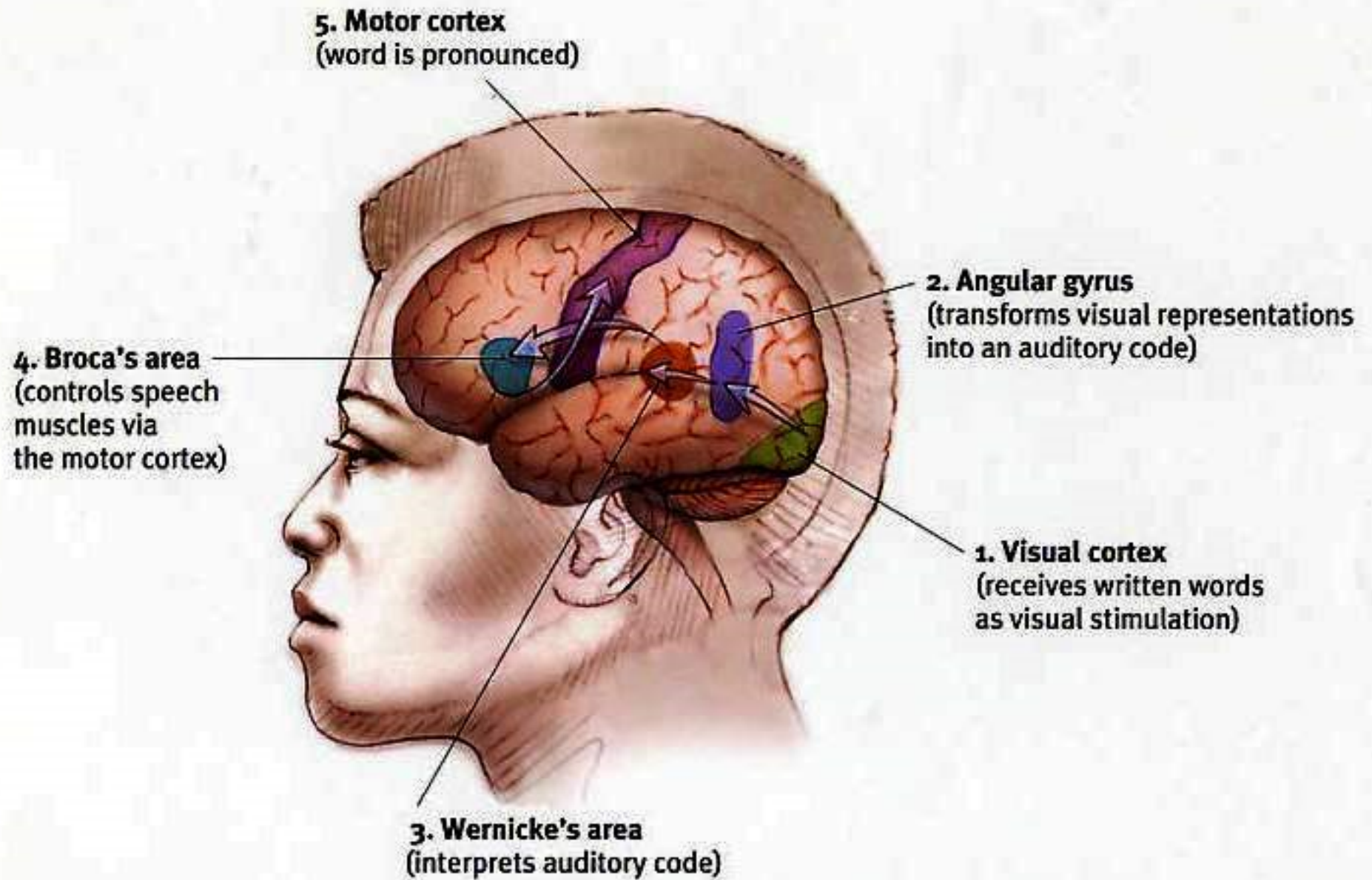
Back to Phantom Limbs

Break

Hearing

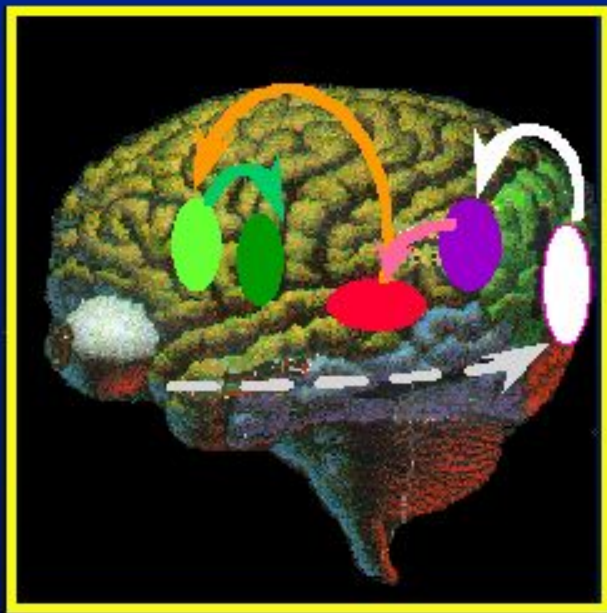




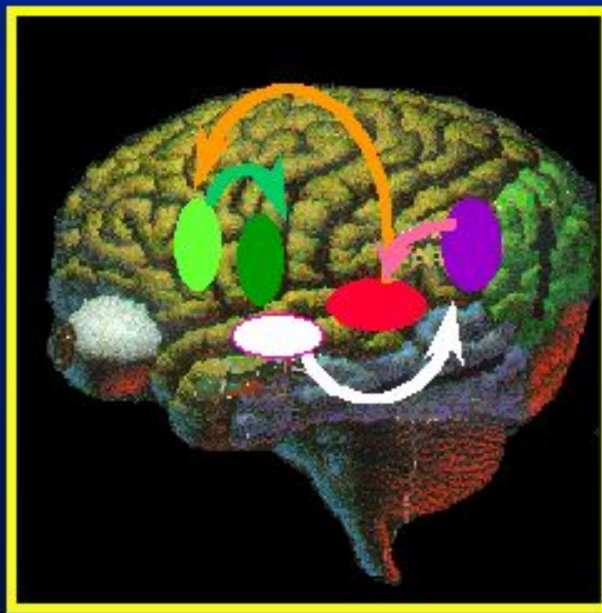


Wernicke's and Broca's Aphasia

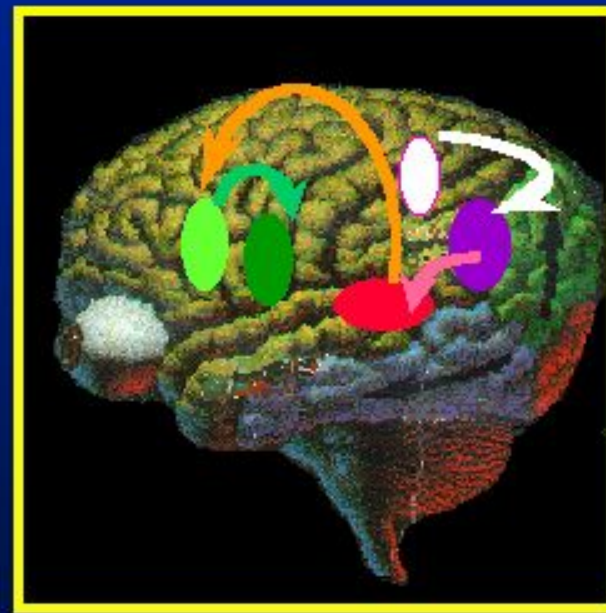Wernicke-Geschwind model of word comprehension and word generation using various input:



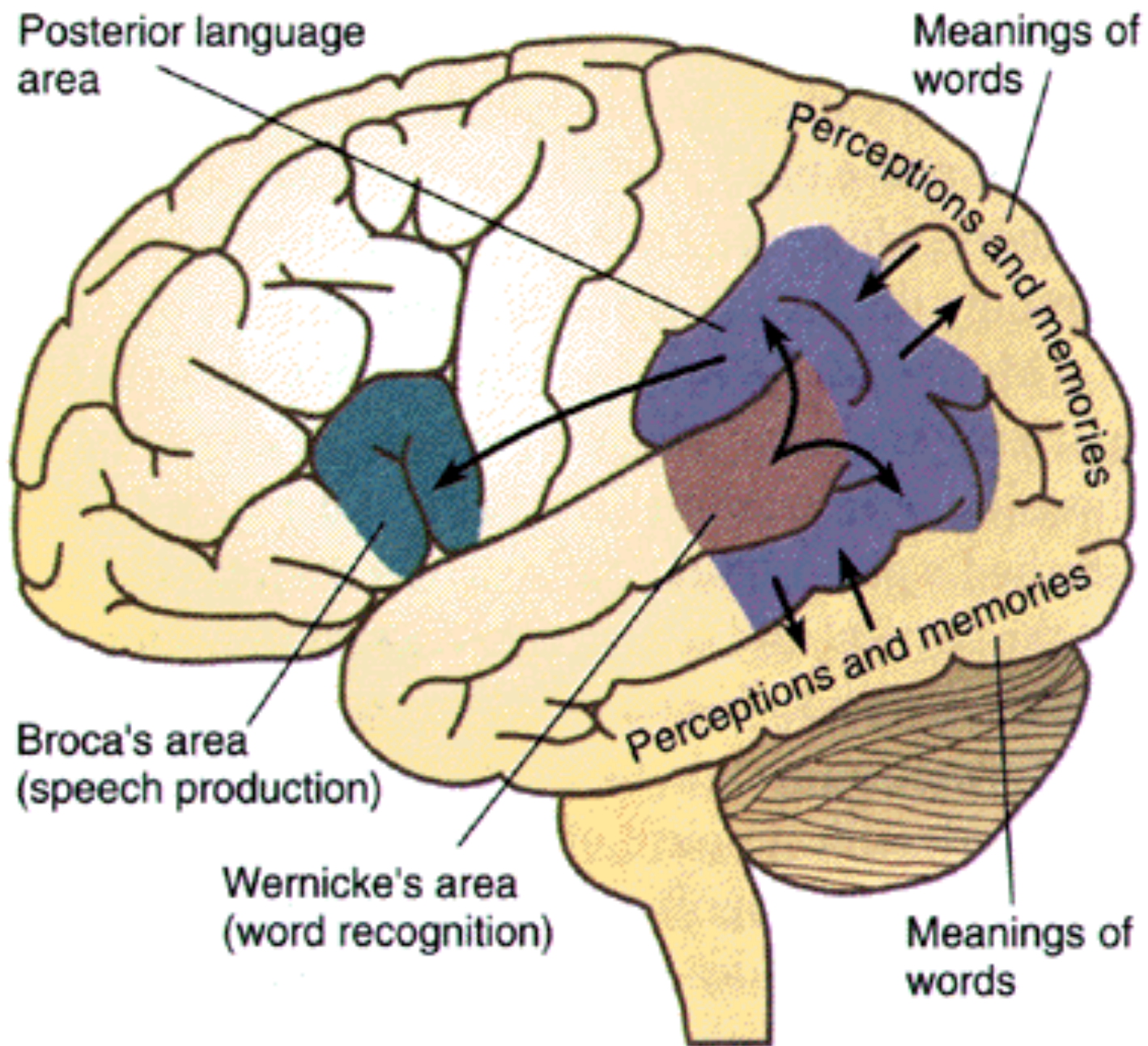
Visual
(reading)



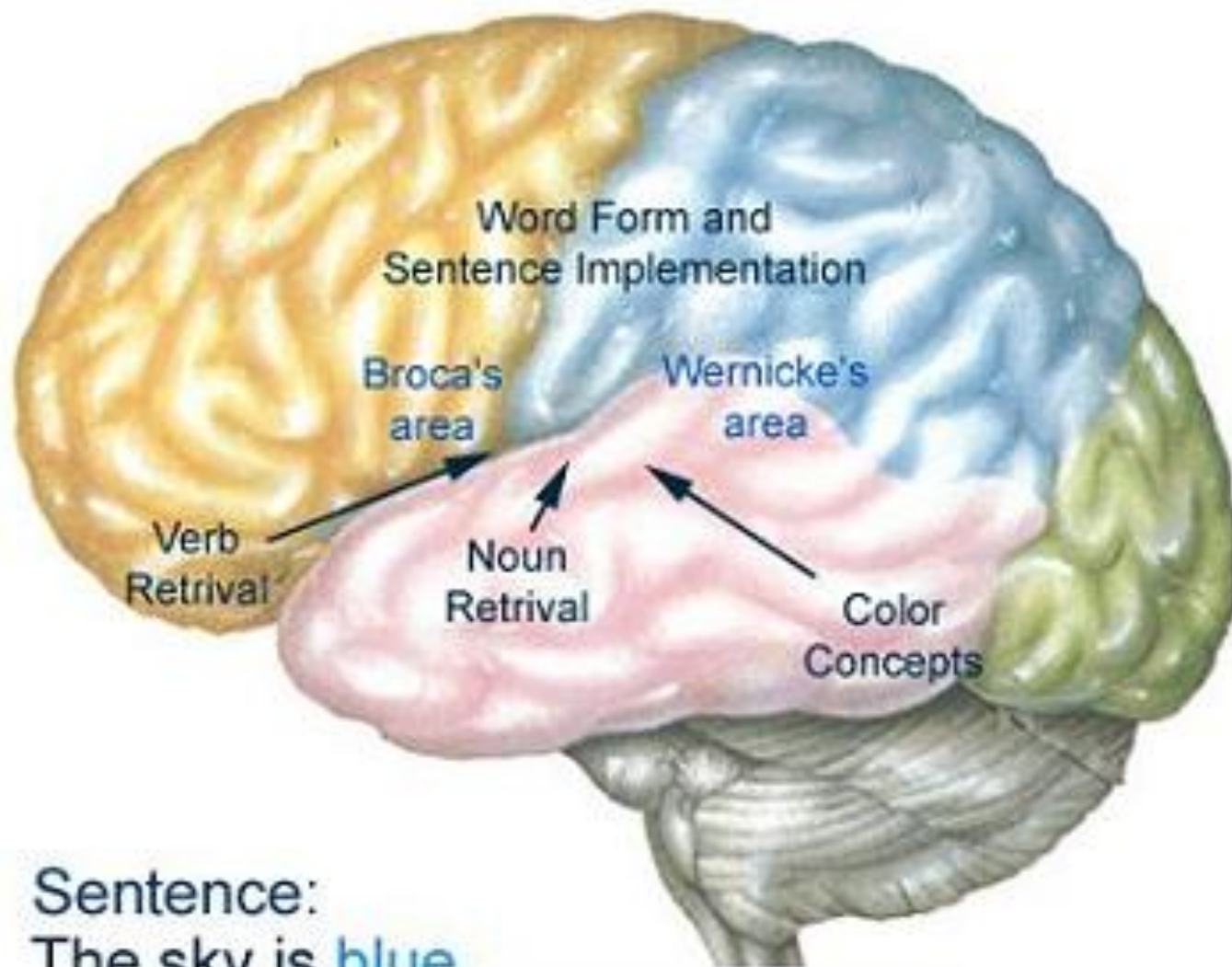
Auditory
(hearing)



Somatosensory
(Braille reading)

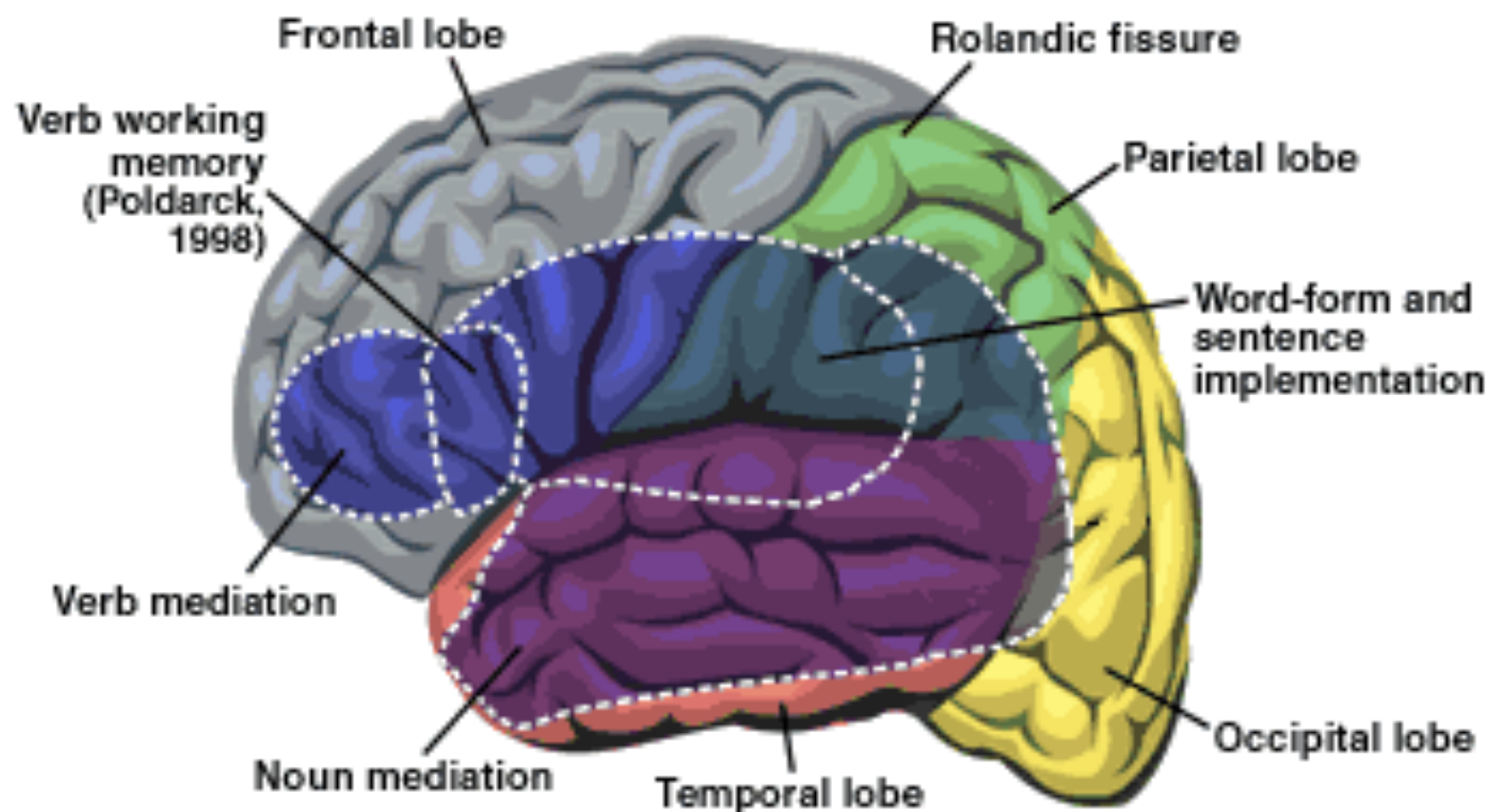


Language involves retrieval of information from many brain areas.



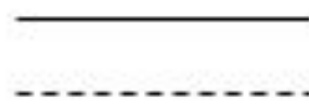
Sentence:
The sky is blue.

The Organization of the Human Brain for Language

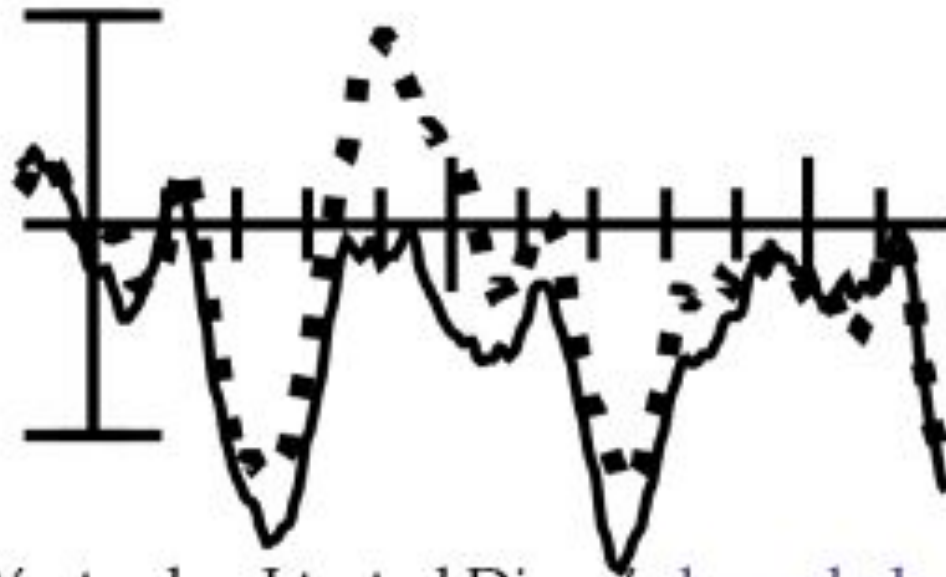


Source: Damasio and Damasio, 1993

CZ



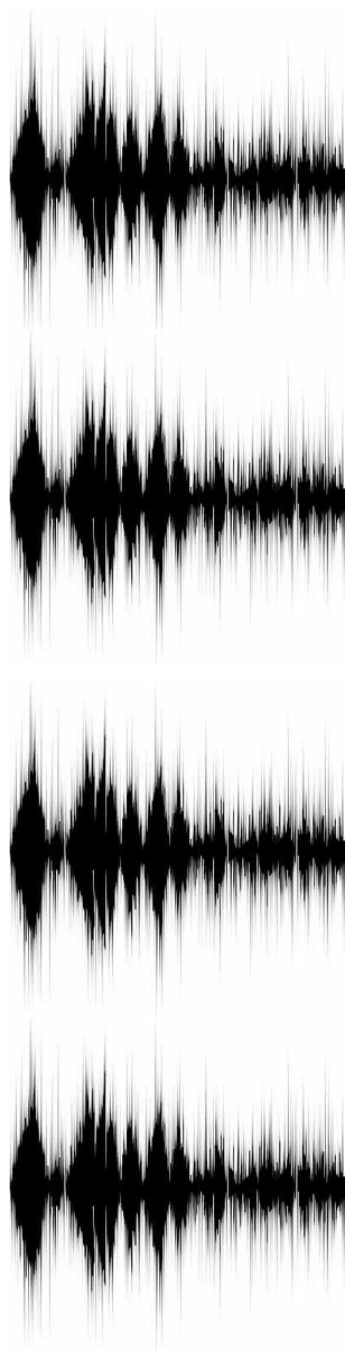
Semantically correct
Semantically incorrect

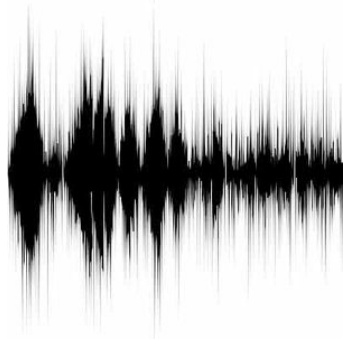
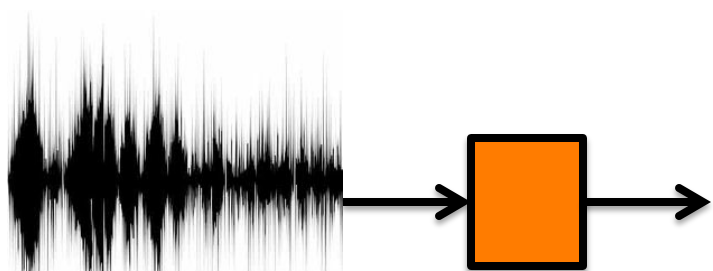
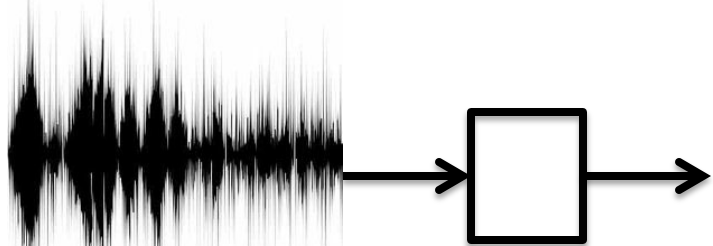
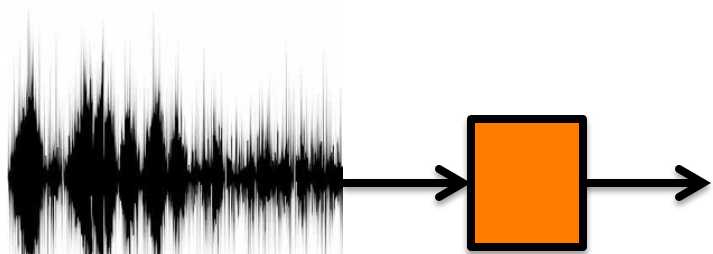


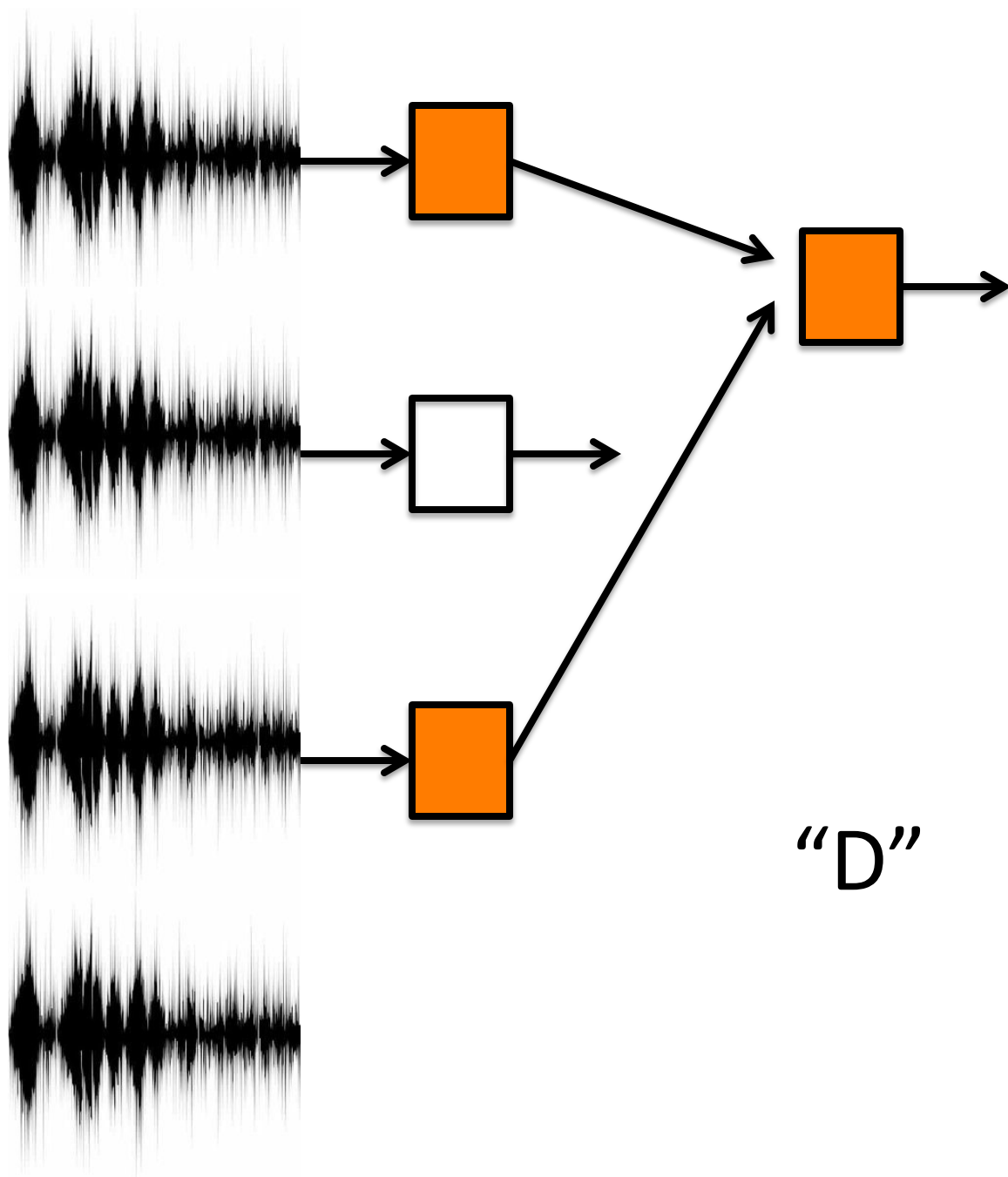
———

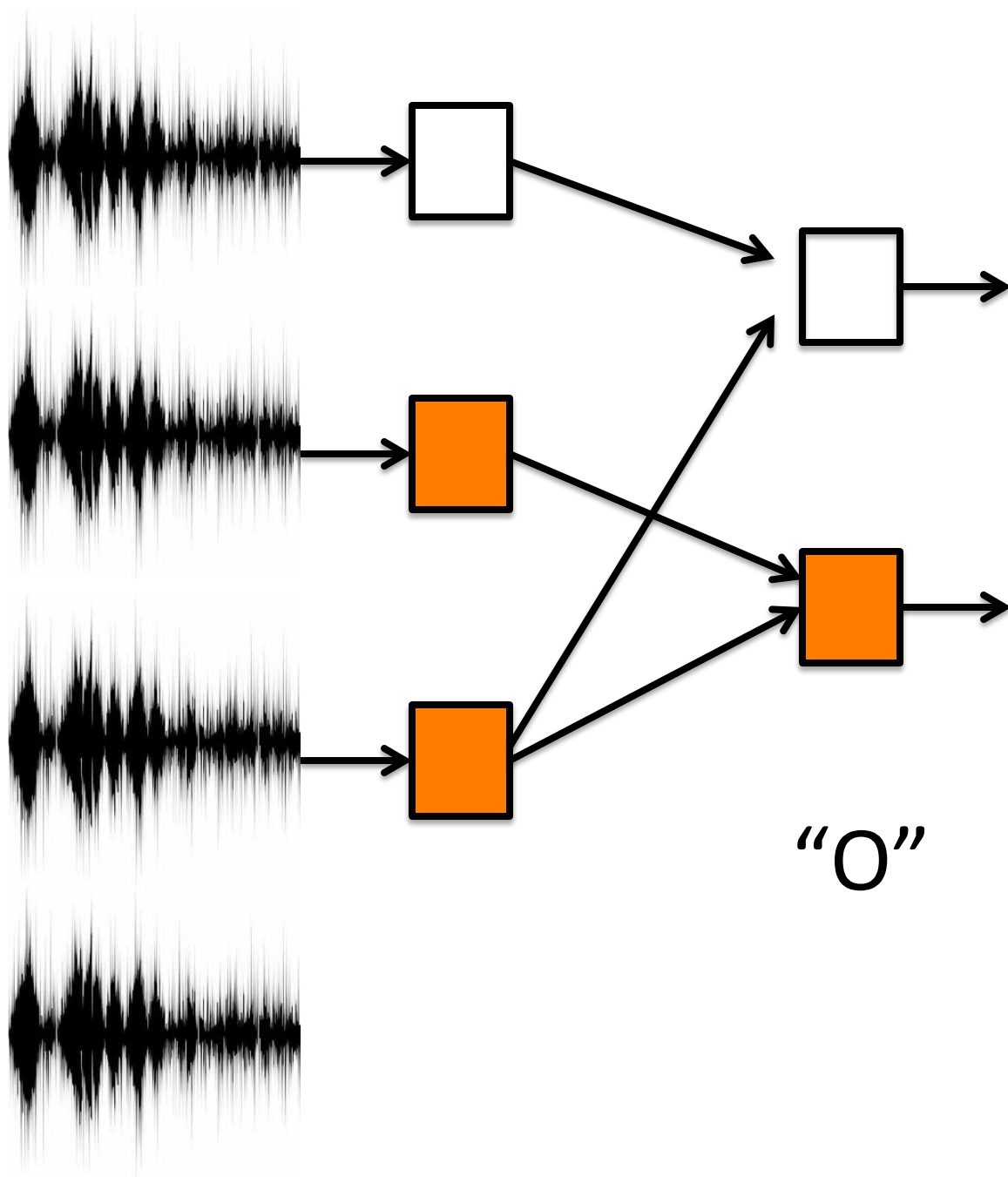
Yesterday I tested Diane's **knowledge** of the issue.

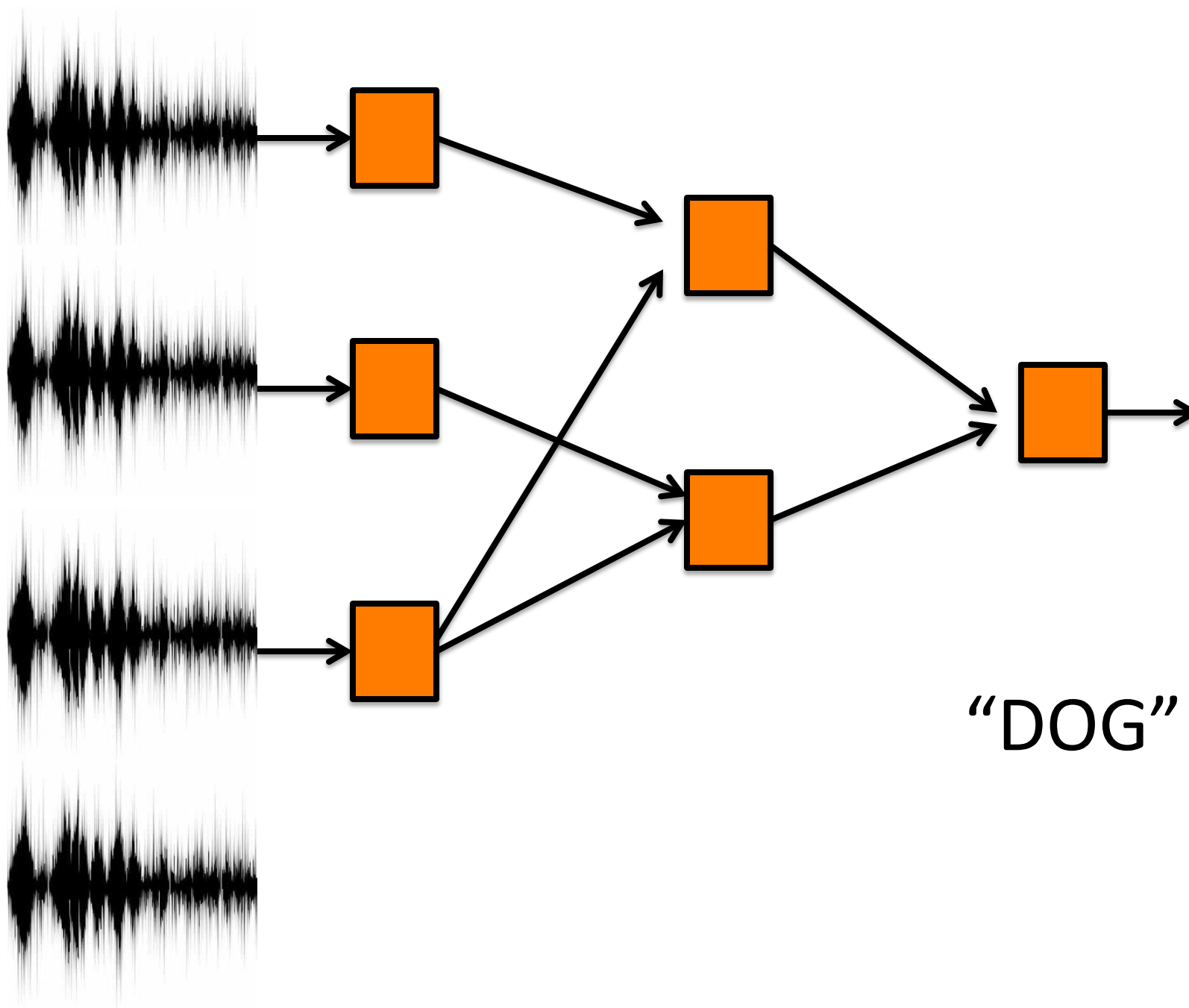
Yesterday I tested Diane's **broccoli** of the issue.





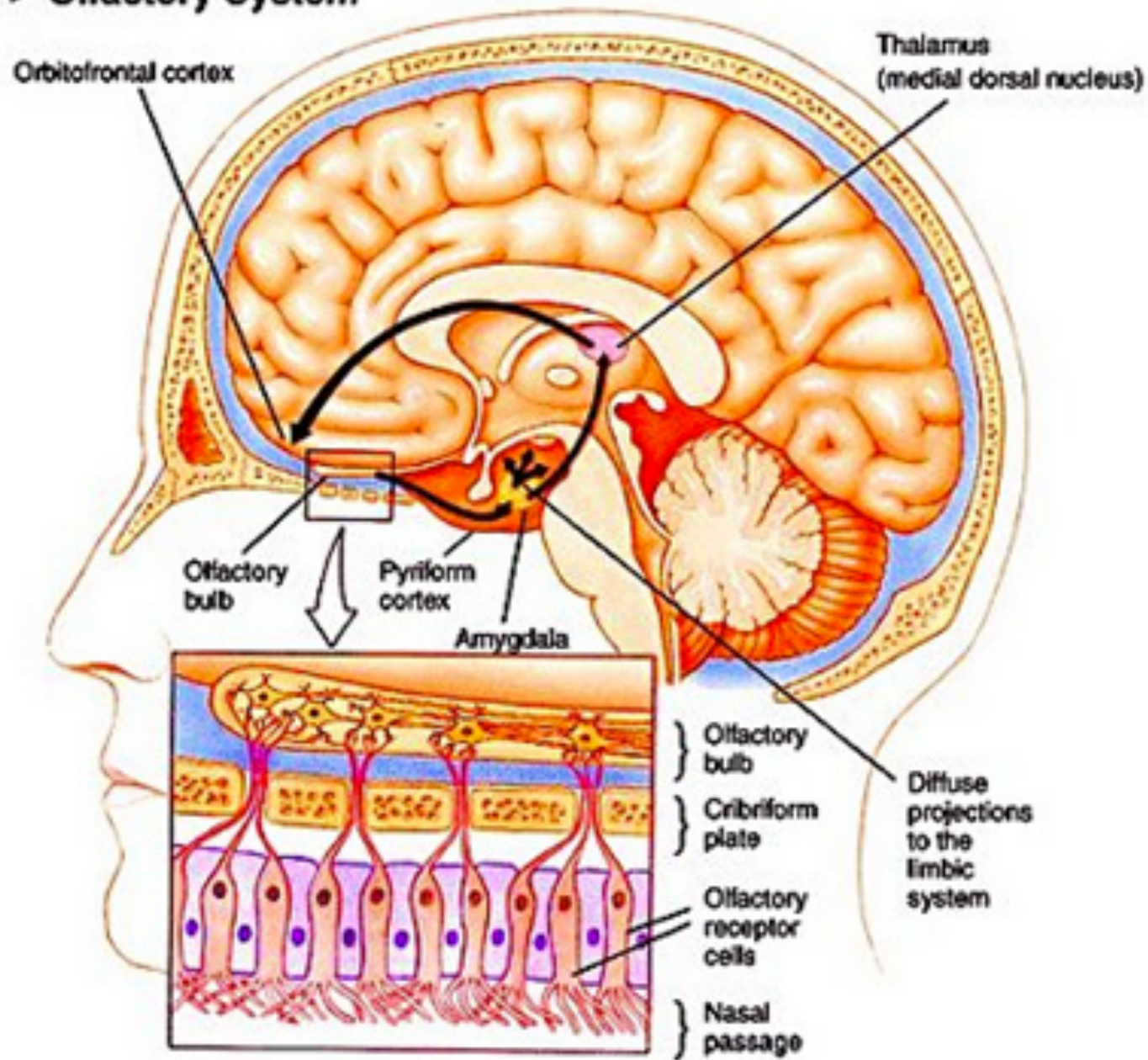


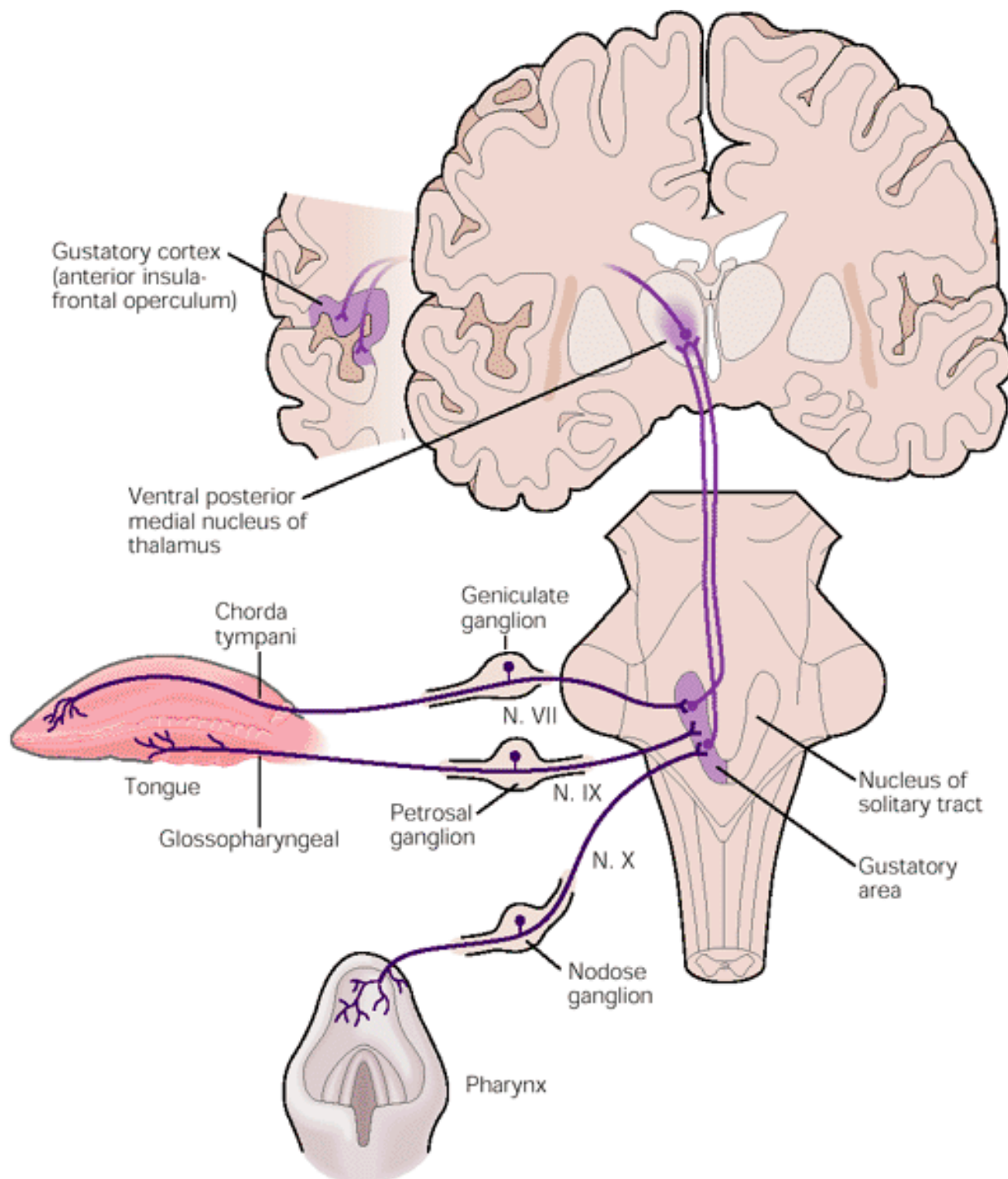
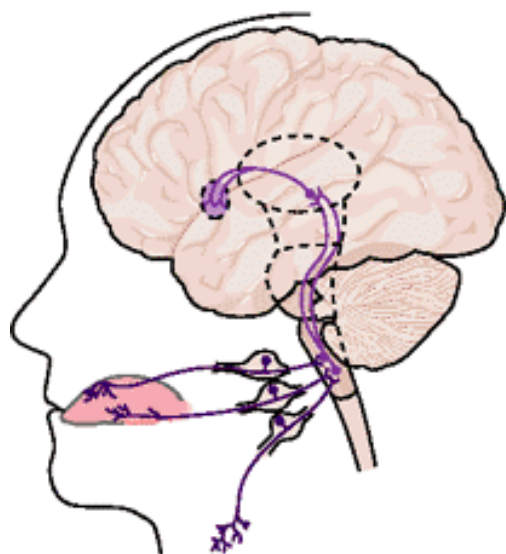




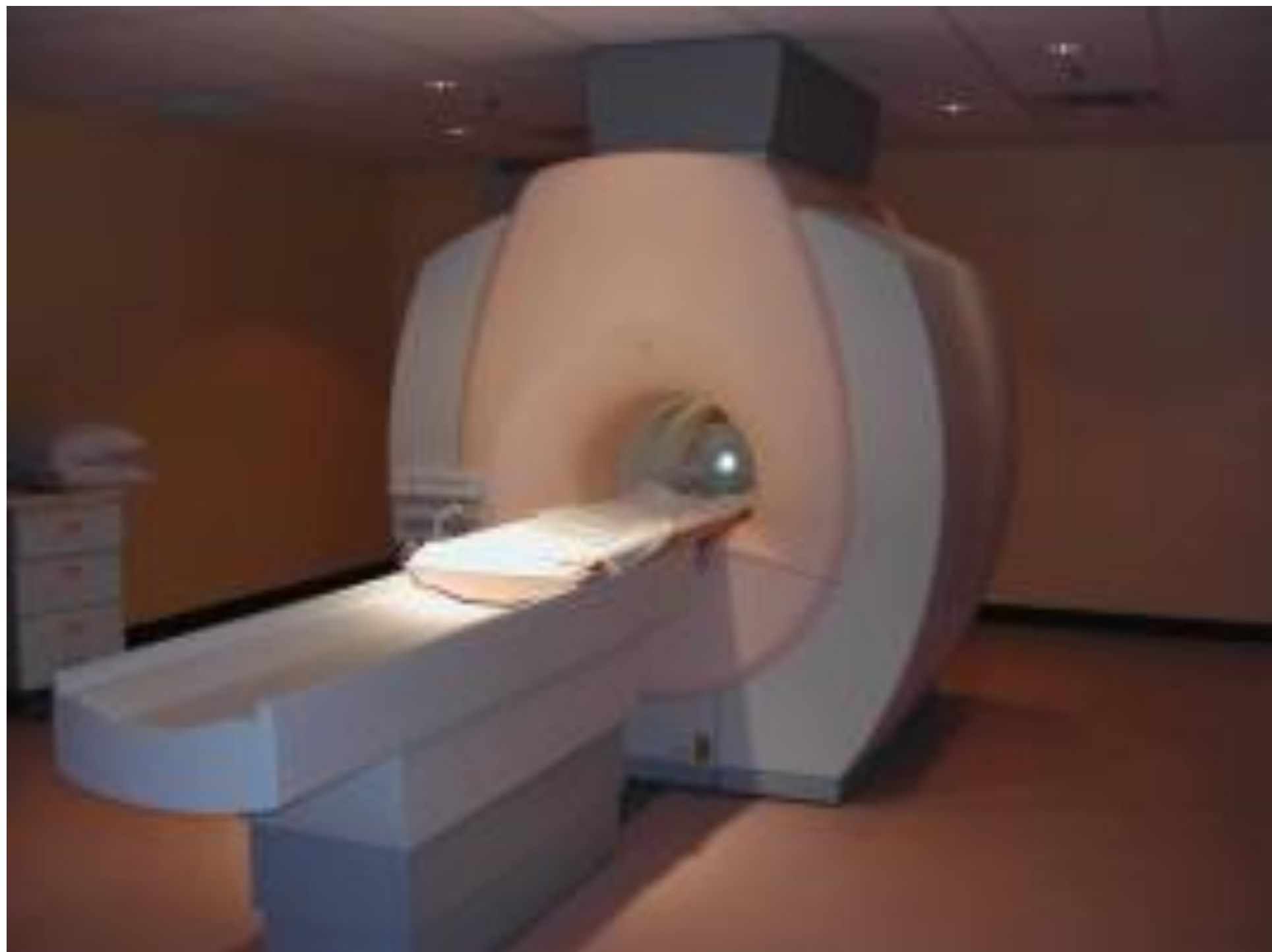
"DOG"

► Olfactory System



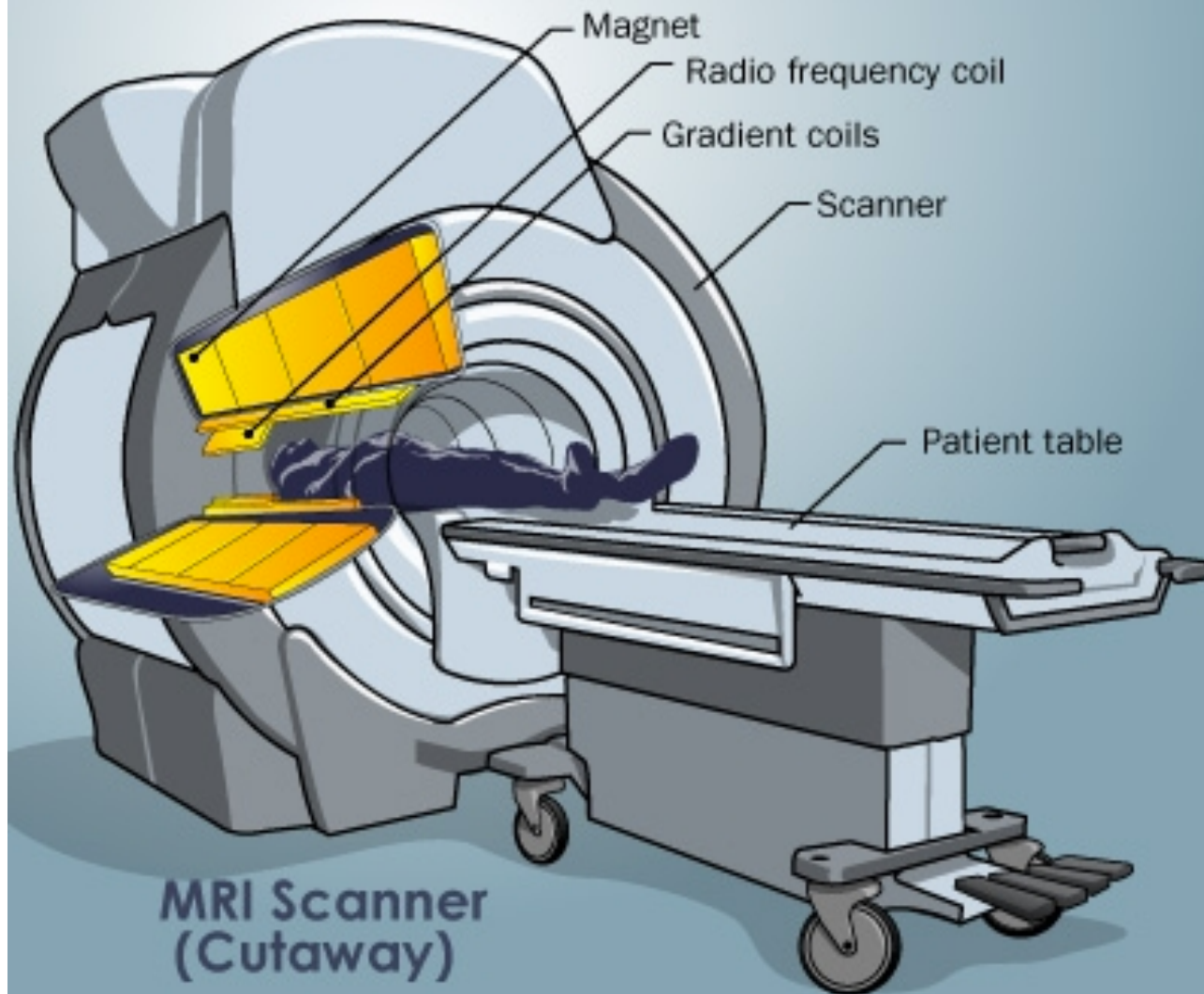


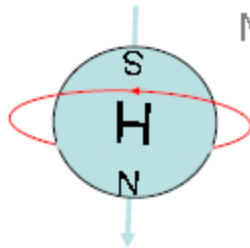
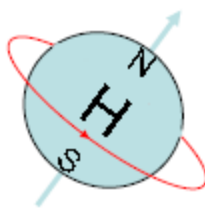
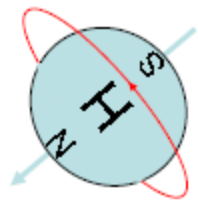
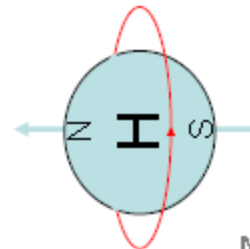
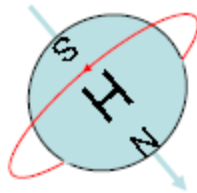
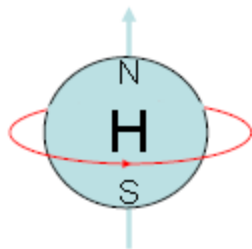
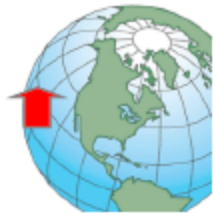Magnetic Resonance Imaging



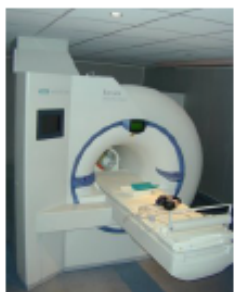How MRI Works

©2008 HowStuffWorks

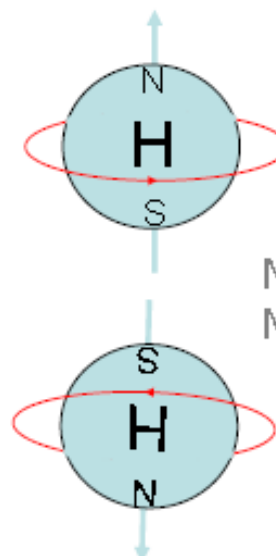
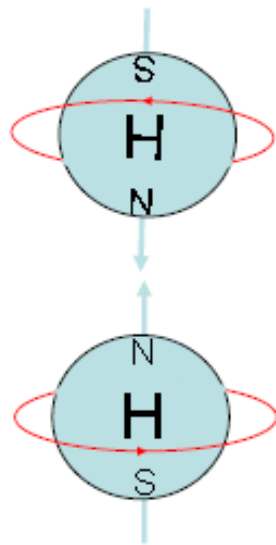
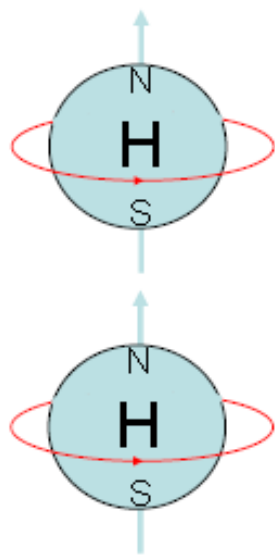




Net
Magnetisation ●

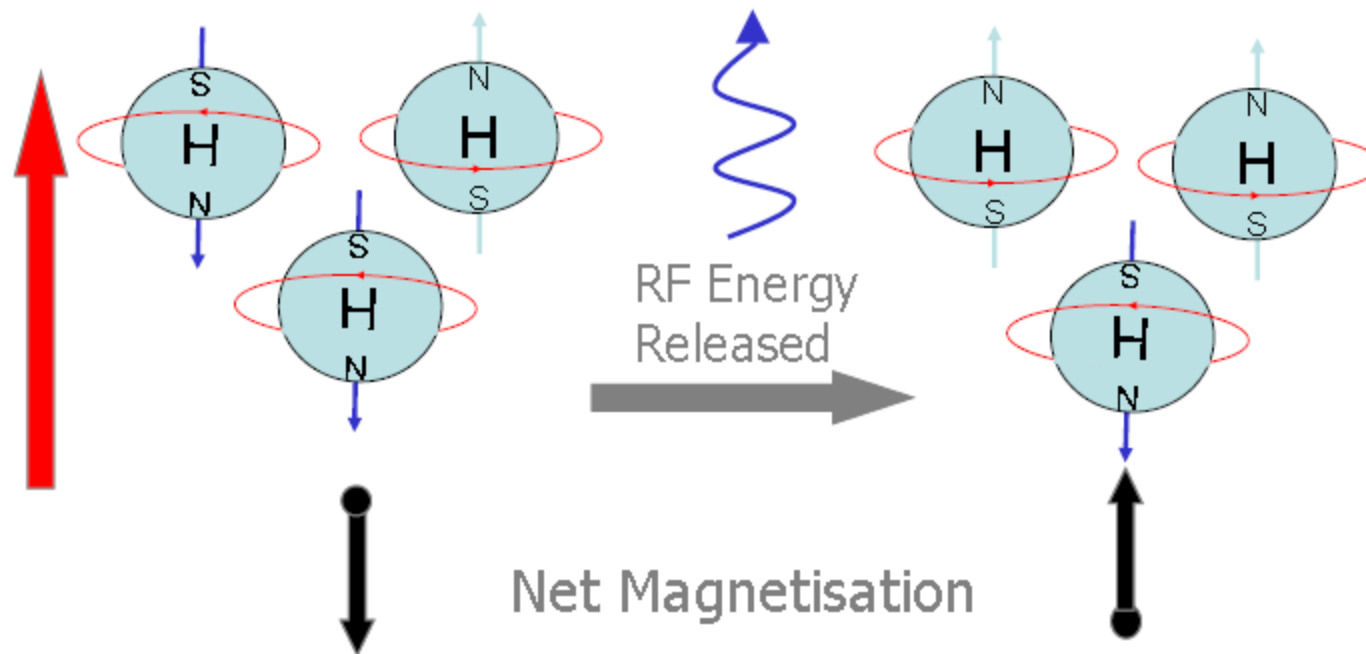


External
Magnetic
Field




Net
Magnetisation





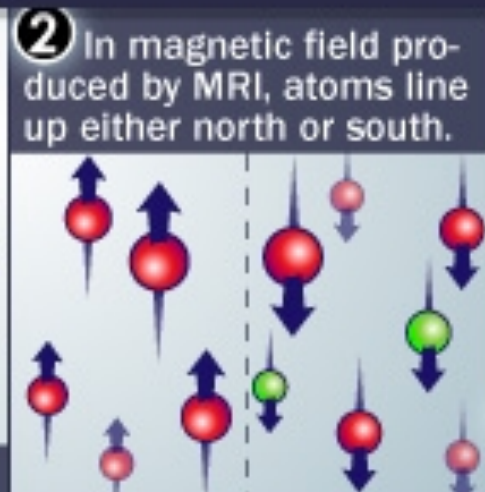
How MRI Works

©2008 HowStuffWorks



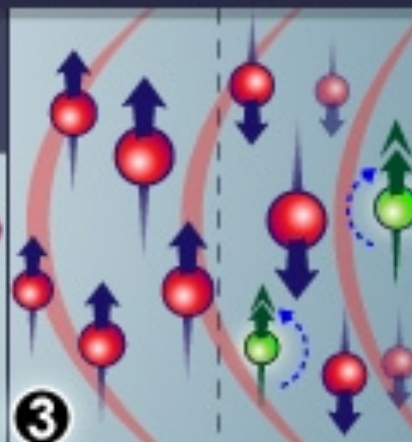
1

Atoms spin in random directions, like tops, around their individual magnetic fields.



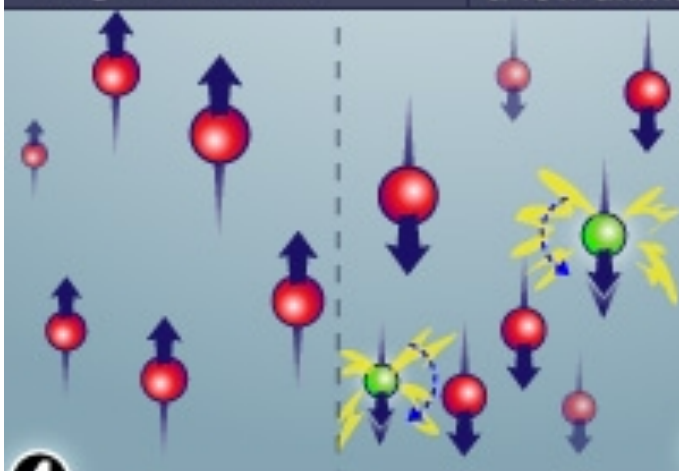
2 In magnetic field produced by MRI, atoms line up either north or south.

About half the atoms go each way, but there are a few unmatched atoms.



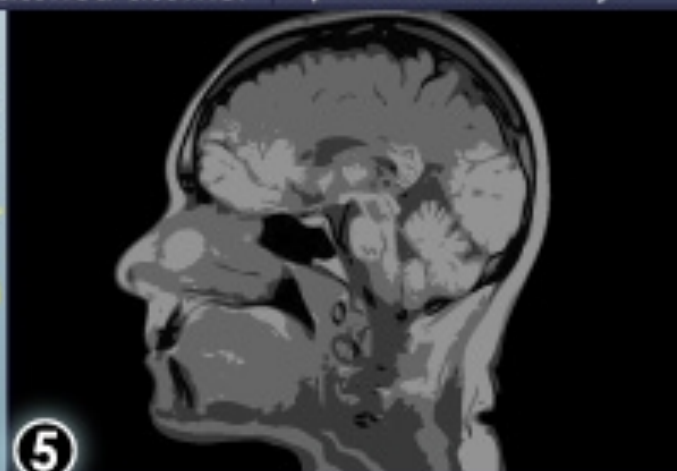
3

When radio frequency pulse is applied, the unmatched atoms spin the other way.



4

When the radio frequency is turned off, the extra atoms return to normal position, emitting energy.



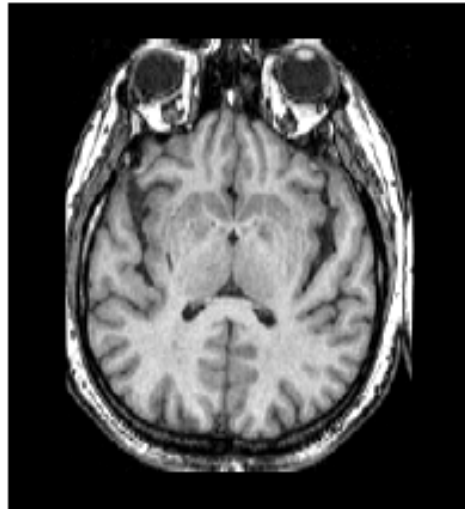
5

The energy sends a signal to a computer. The computer uses a mathematical formula to convert the signal into an image.

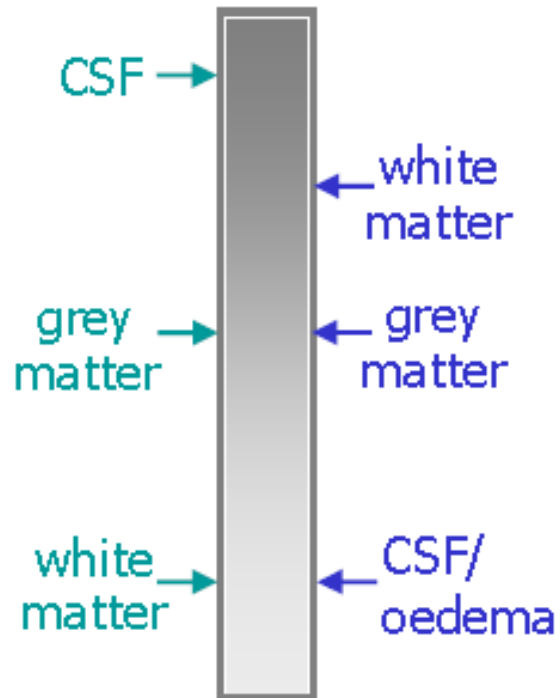


RF Energy
Released

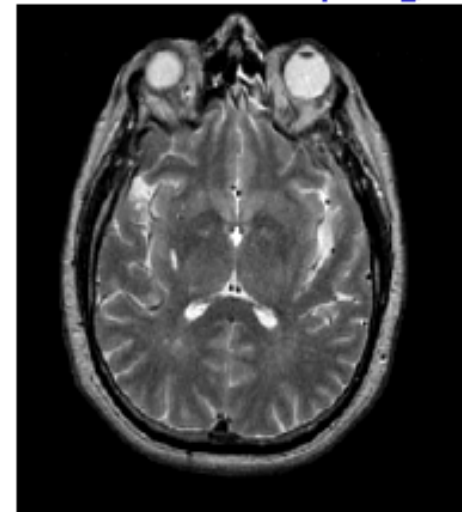
T1: wait short time
before sampling



- most useful for
anatomical detail



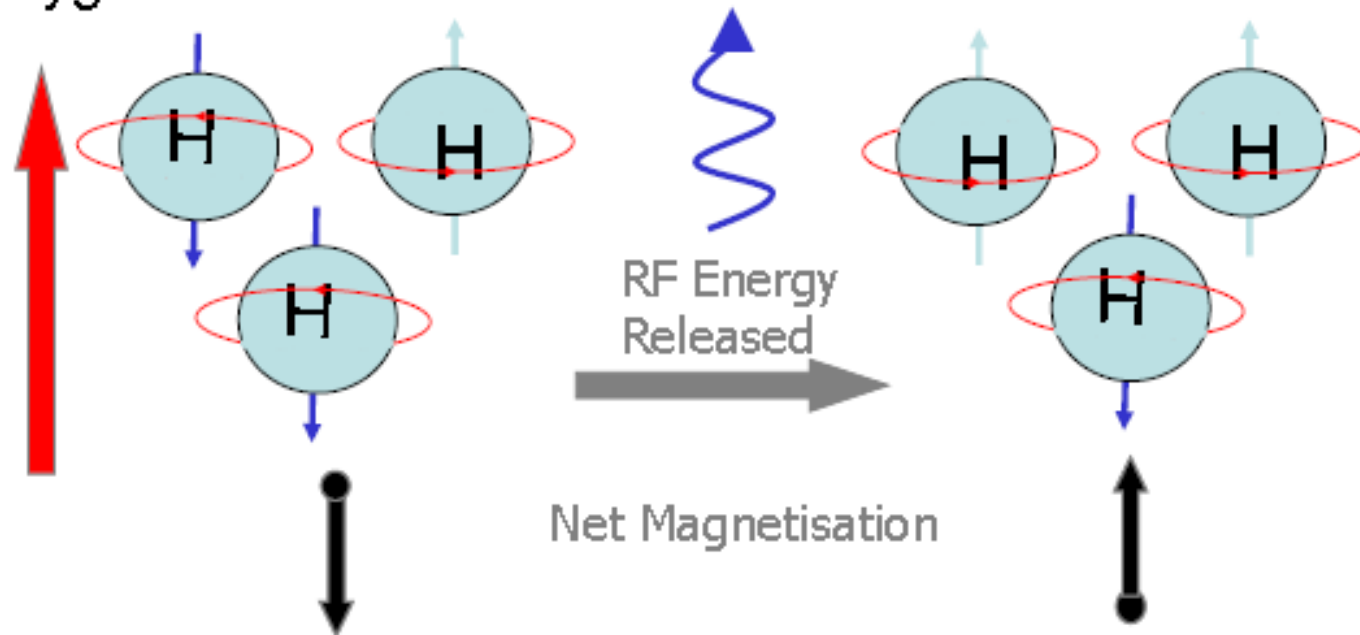
T2: wait longer time
before sampling



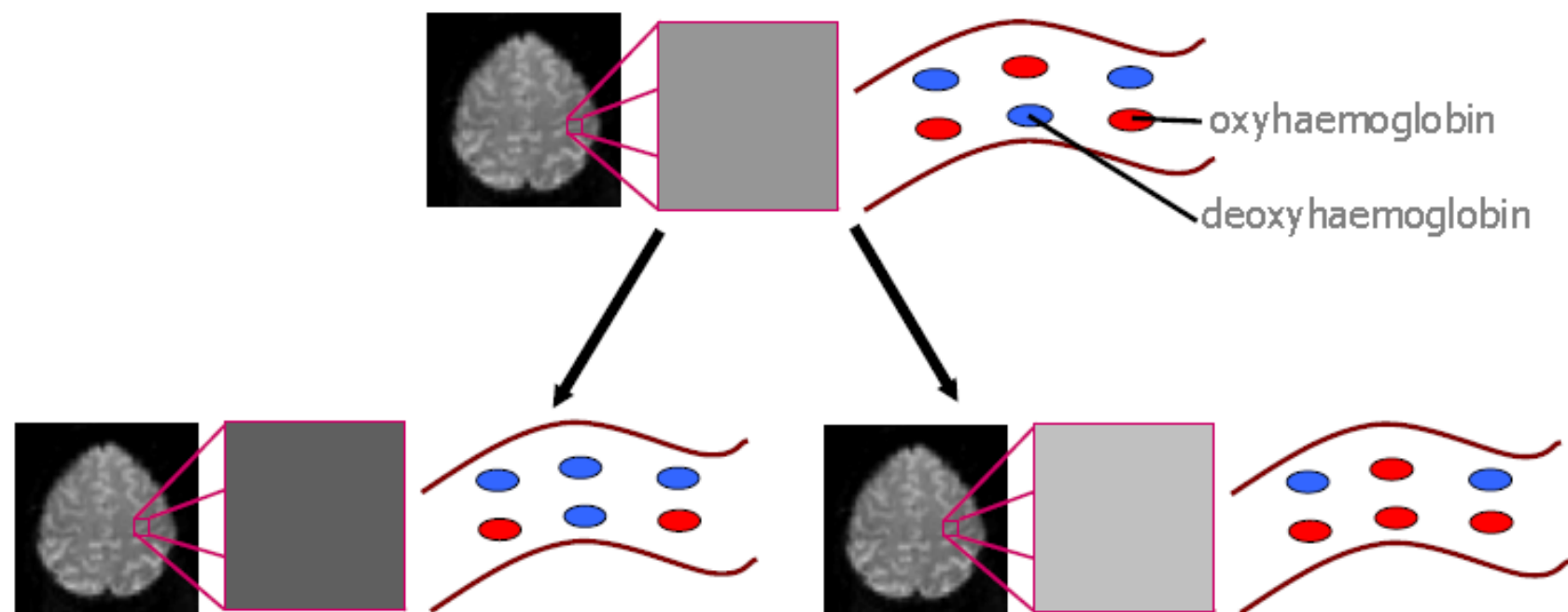
- most useful for
pathological changes.

Functional Magnetic Resonance Imaging

Uses MRI scans to access information about changes in oxygenation levels in the brain.



Rate at which radiofrequency energy is lost can be influenced by alterations in the local oxygenation levels of the blood in an area of increased neuronal activity.



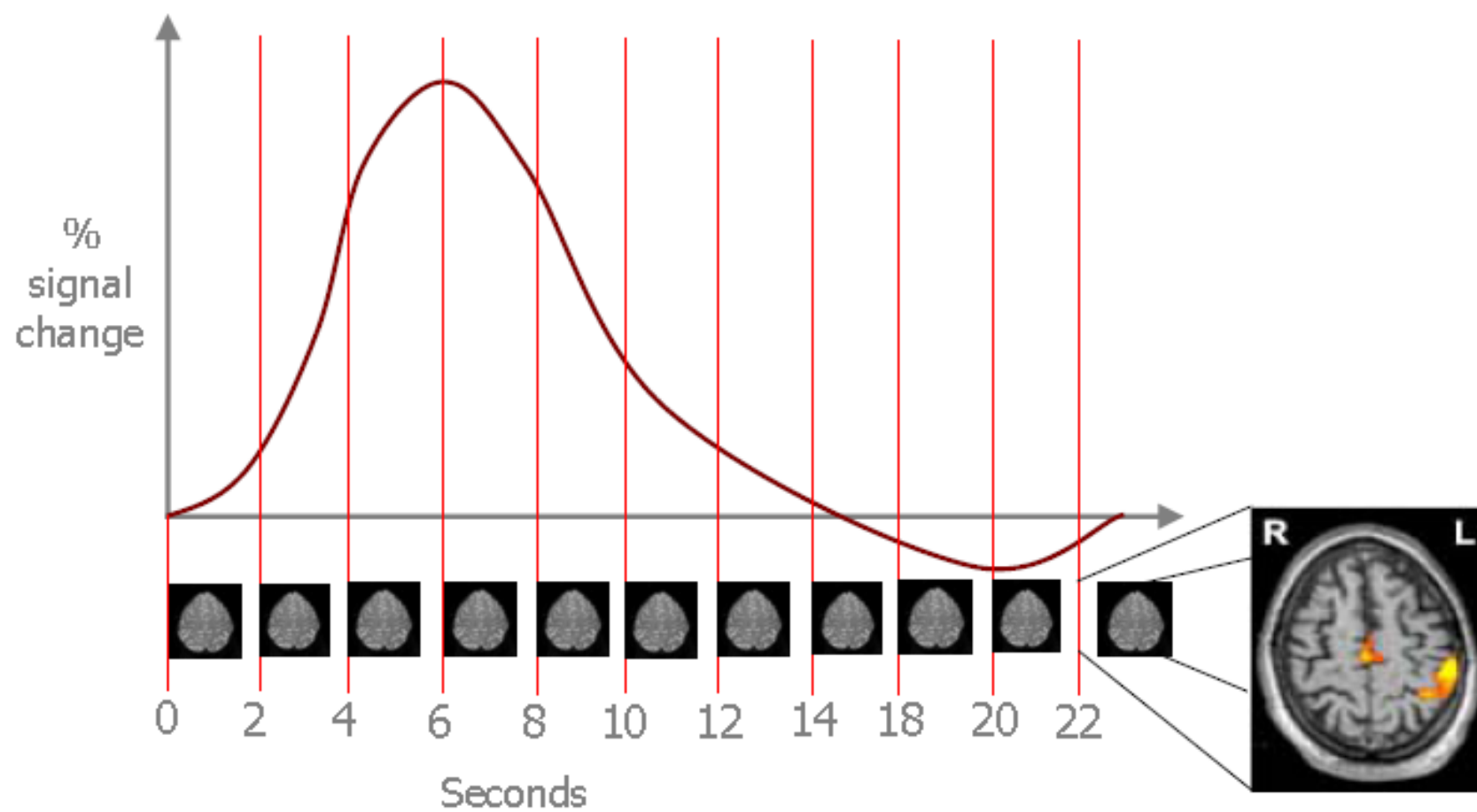
- Increased proportion of deoxyhaemoglobin.
- MRI signal lower = darker

- Decreased proportion of deoxyhaemoglobin.
- MRI signal higher = brighter

This change in signal intensity due to the relative proportions of oxy- and deoxy-haemoglobin is called:

Blood Oxygenation Level Dependent contrast

= **BOLD** Contrast.



READ (80s)

A 38 yr old man, dx 18 yrs ago with ulcerative colitis is referred to your clinic with itching & abnormal liver enzymes.

Medical Hx: Non-smoker. Drinks 1-2 beers/d. No hx of blood transfusions. No IV drug use or high risk sexual behavior. No psych illness. No family hx of liver disease. Has had 3 courses of prednisone for ulcerative colitis flares which happen approximately every 6 yrs.

Recent Hx: Completed course of corticosteroids (prednisone) 6 months ago. Complains of mild, generalized itching for past 3 months. No skin rash noted. Taking Asacol (mesalamine) 3g/d for ulcerative colitis maintenance.

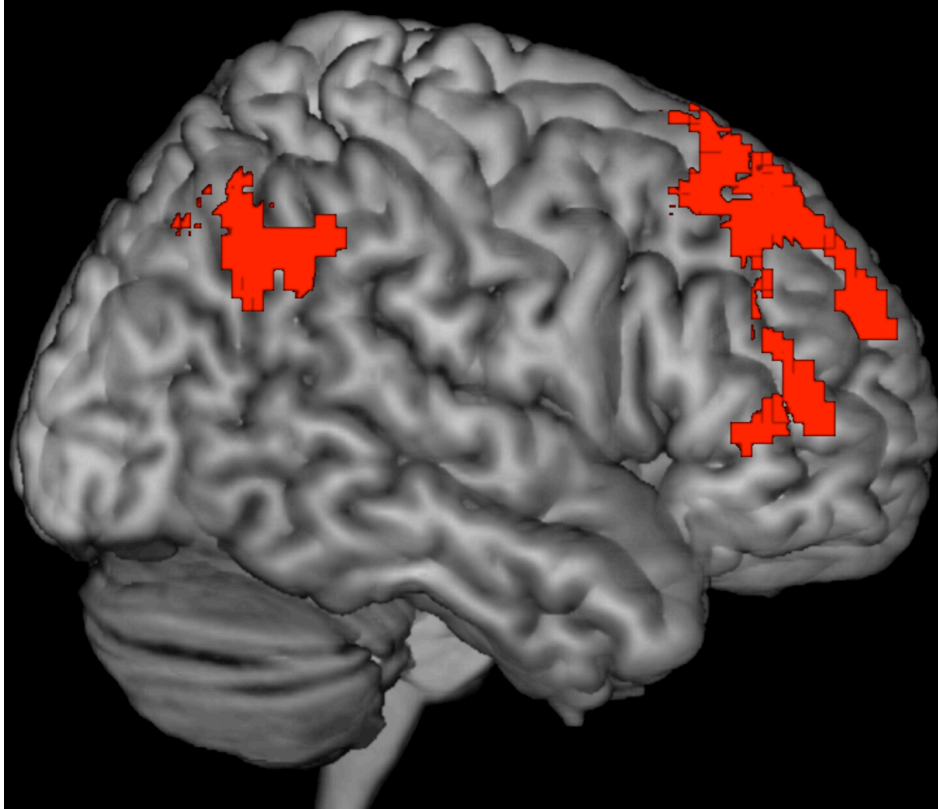
Assessment: No diabetes, joint pains or lung disease.

Physical exam normal. Normal BMI. Has 1 soft non-bloody BM/d.

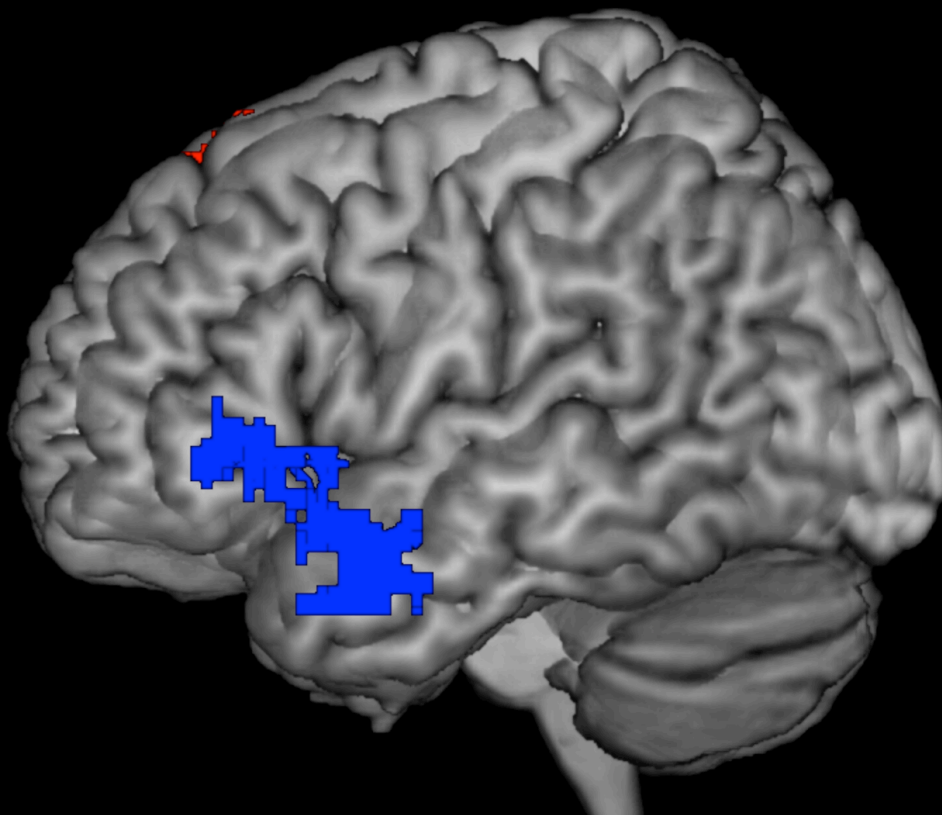
Eating well. No abdominal pain. Ultrasound reveals normal gallbladder with no biliary dilatation.

ALT 45 (7-40)	AST 32 (5-35)	Alk Phos 536 (30-145)	GGT 540 (20-35)	INR 1.0 (0.9-1.1)
Total Bili 12 (5-22)	Hgb 155 (140-180)	WBC 9.1 (3.5-12)	PLT 180 (150-400)	

Right



Left



Experts
Holistic, Experience Based Imagery

Novices
Analytic, Book Based Knowledge